

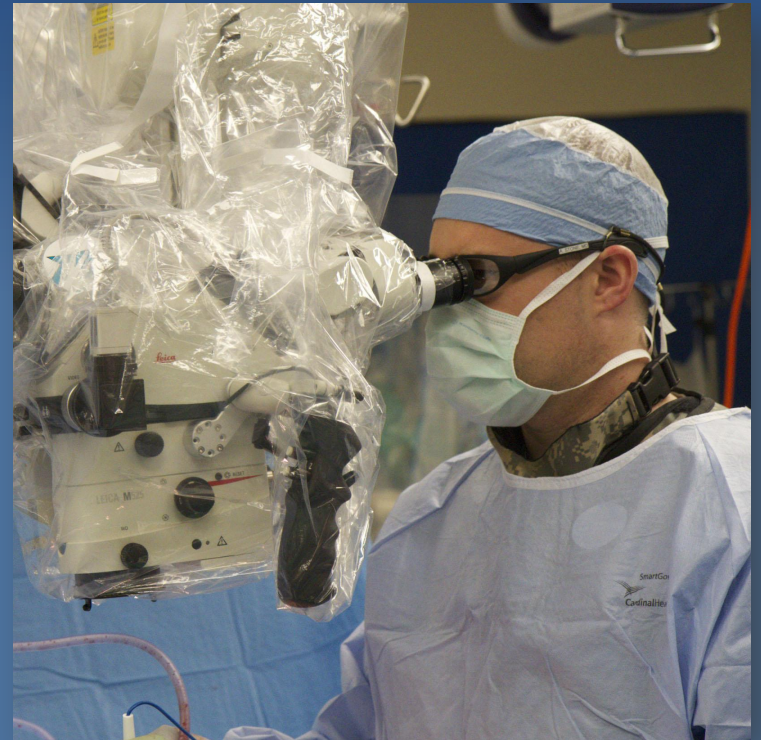Caring for Your Back: Surgical and Non-Surgical Options

Addison Stone, M.D.
Board Certified Spine Surgeon
Specializing in Minimally Invasive
Spine Surgery

April 20, 2017

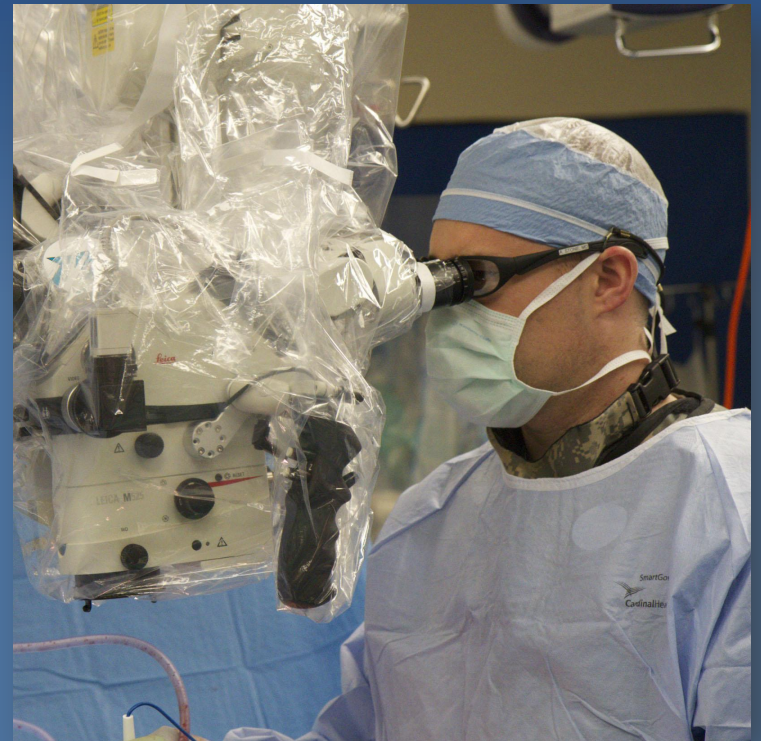My Practice

- Board certified:
American Board of
Orthopaedic Surgeons
(ABOS)
- 100% spine
- Minimally invasive spine
surgery



My Practice

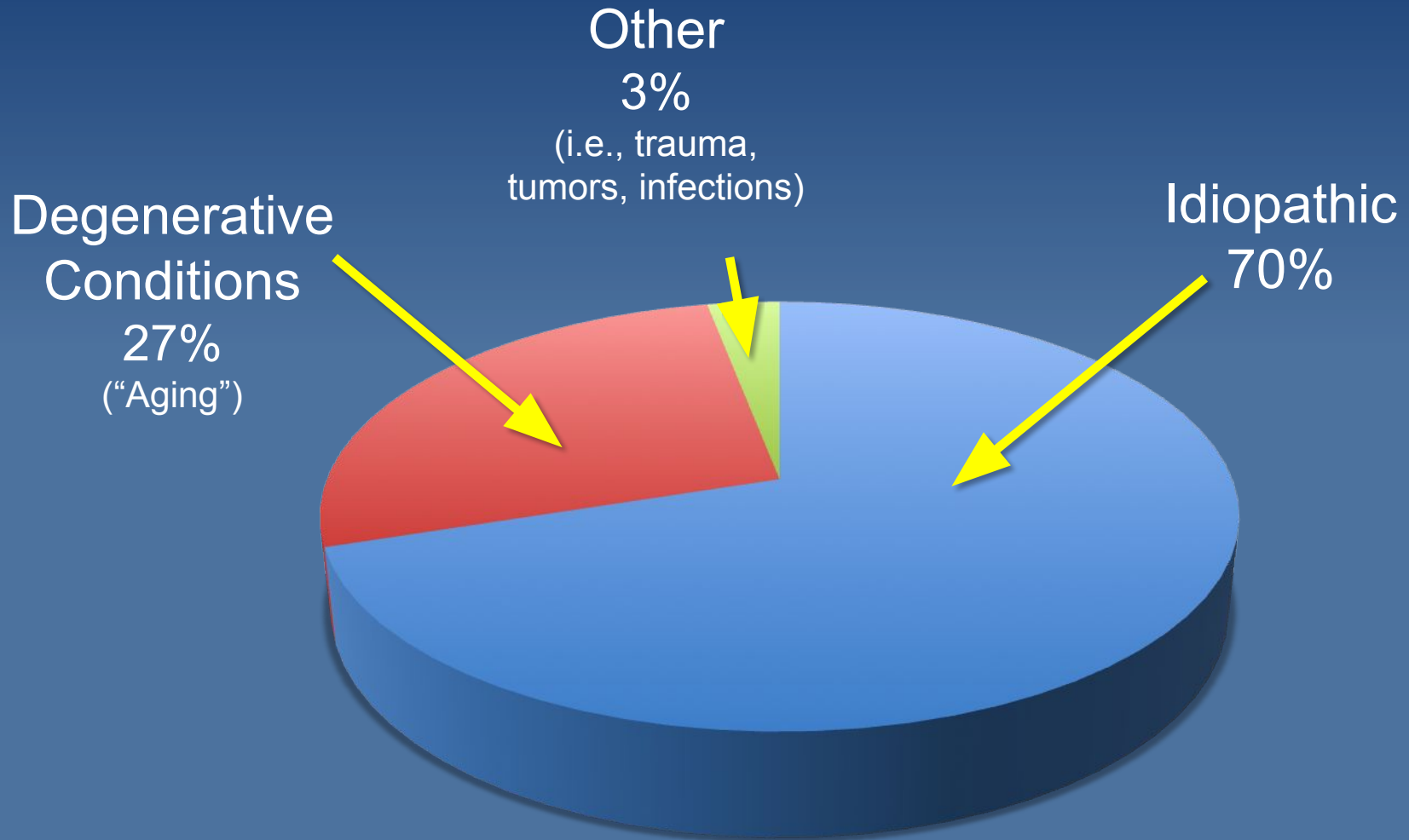
- Adult & pediatric
- Scoliosis and degenerative spine conditions
- Disc replacement
- Computerized spine navigation



Objectives

- Degenerative conditions affecting the spine
- Anatomy of the spine
- Surgical & nonsurgical treatment options

Spinal Conditions

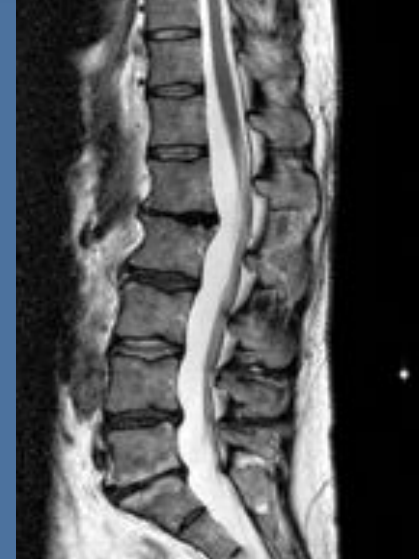
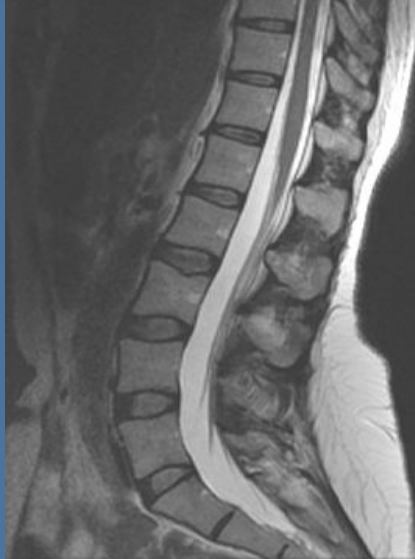

What are Degenerative Conditions?

- Natural Aging-
“Wear and Tear”
- The Snap,
Crackle, and Pop
Years

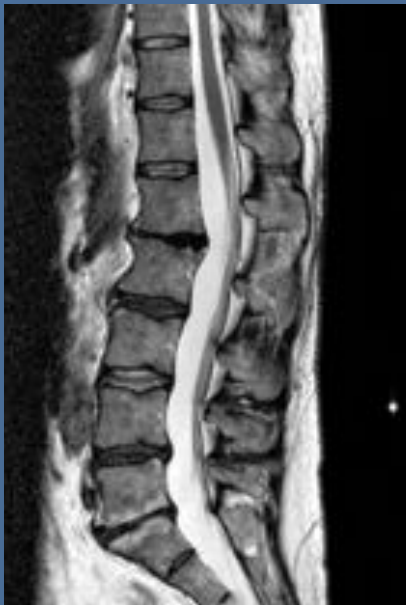


What Happens with Age?

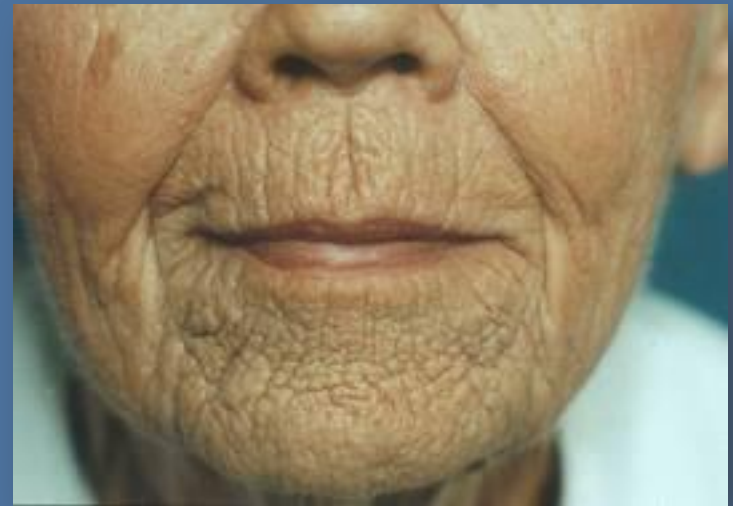

Degenerative Conditions

Degenerative
conditions of the
spine



Wrinkles

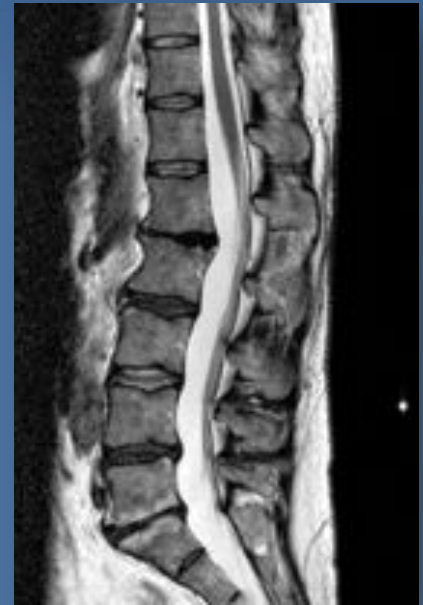


Causes of Degenerative Conditions

Genetics

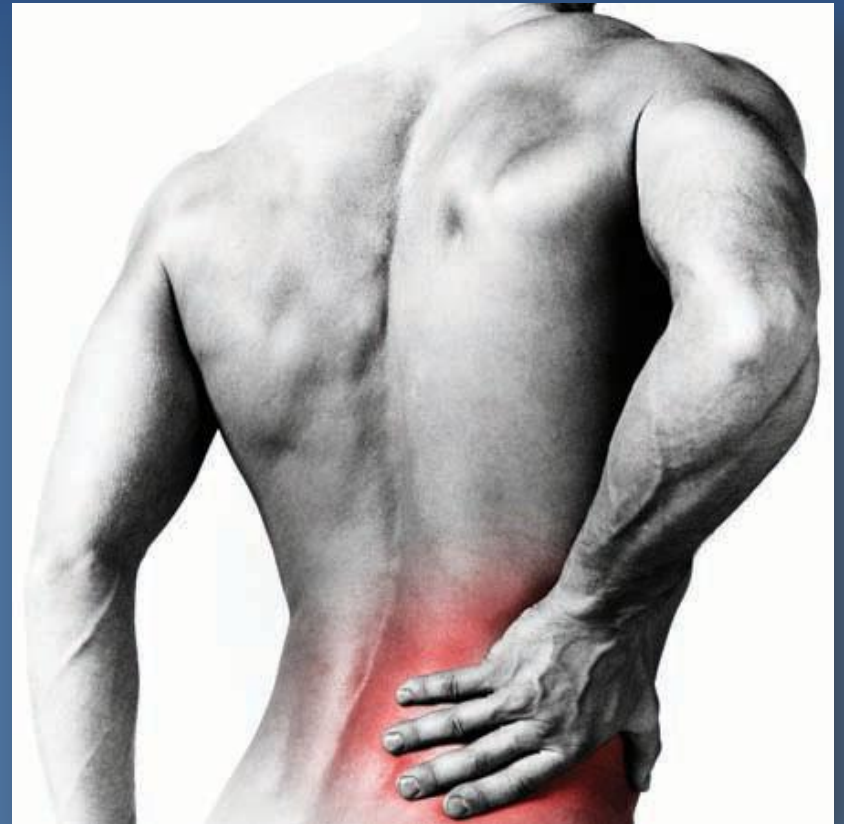


Environmental Factors



Degenerative Conditions

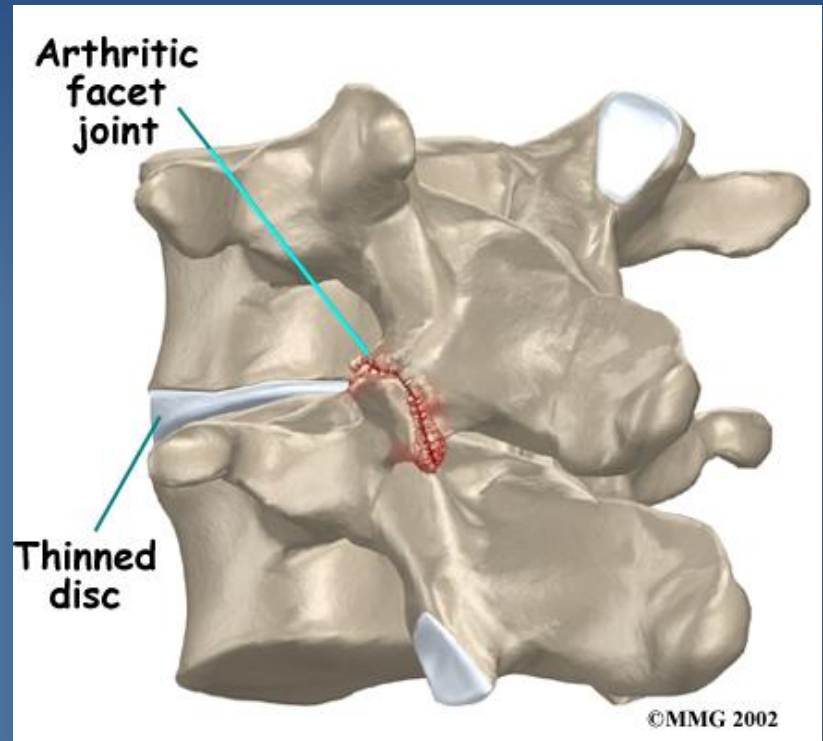
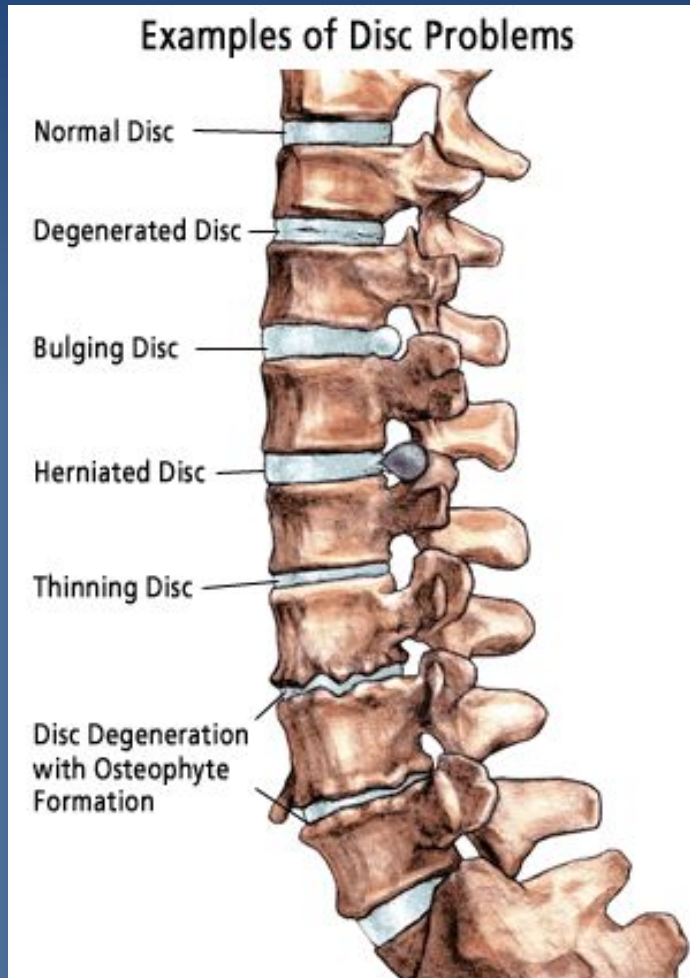
1. Degenerative Discs/
Facet Arthritis
2. Disc Herniations
3. Spinal Stenosis
4. Spondylolisthesis



#1

Degenerative Discs & Facet Arthritis

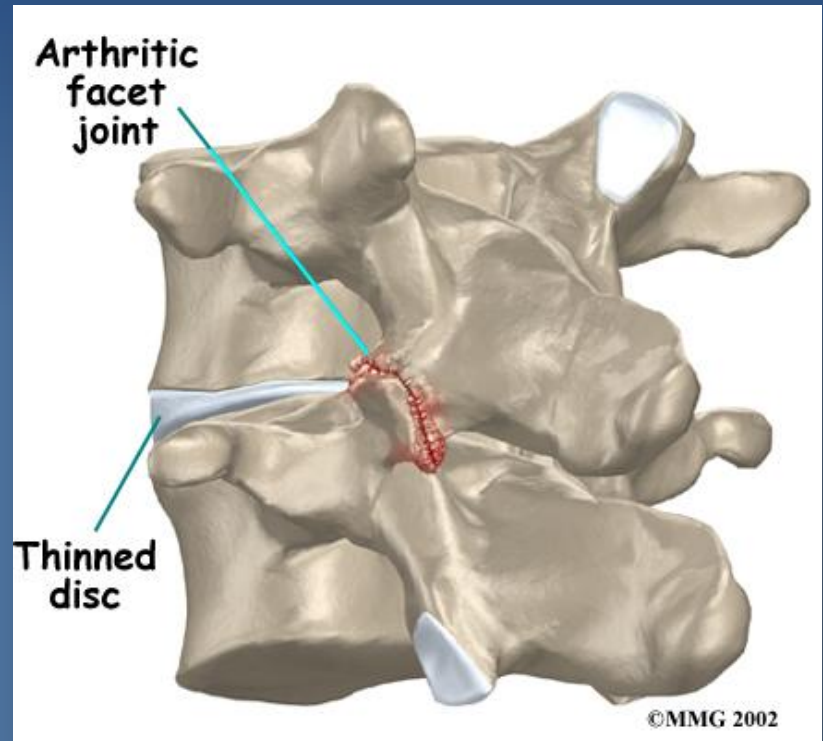
Degenerative Discs & Facet Arthritis



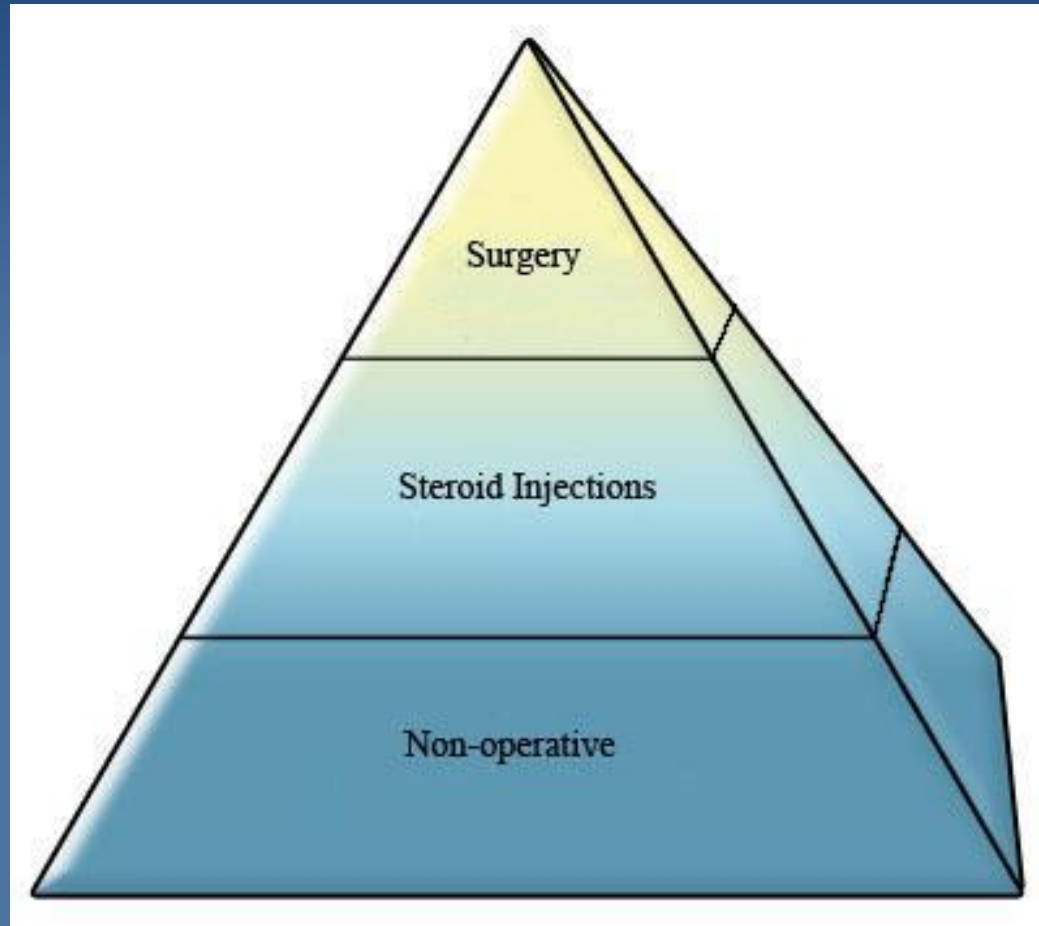
Degenerative Discs & Facet Arthritis

Symptoms

- Localized pain
- Neck/ shoulder pain
- Back/ buttock pain



Three Tiers of Treatment

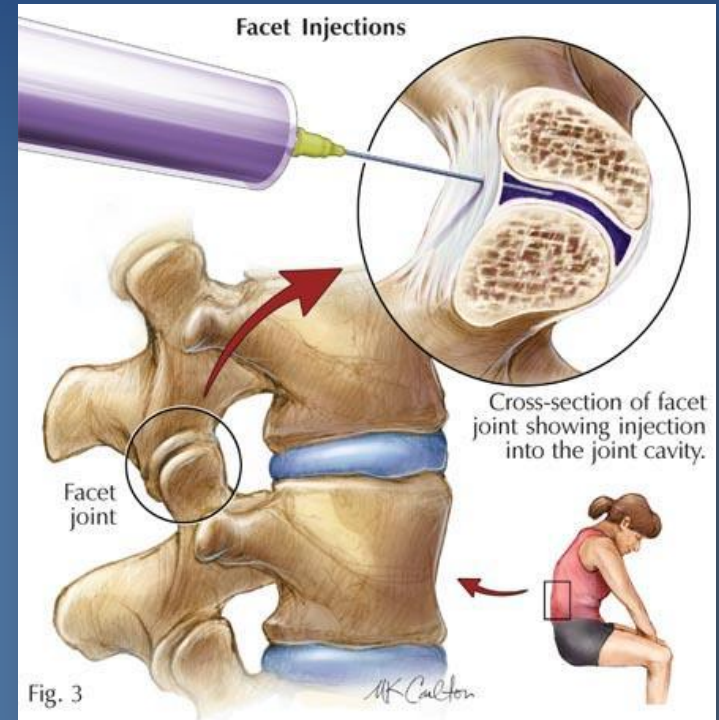
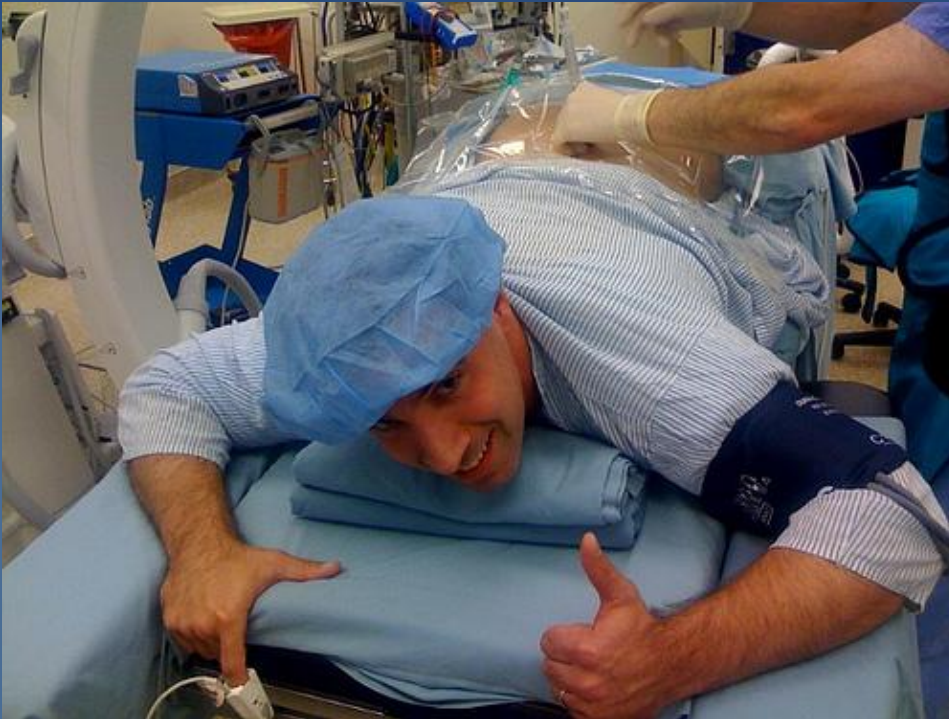

Tier #1

Non-operative Treatment

- Rest/activity modification
- Ice/heat
- NSAID's (limit narcotics)
- Muscle relaxants
- Short course of oral steroids
- Weight loss
- Physical therapy
- Posture/ergonomics
- Massage
- Acupuncture
- Chiropractic
- Tincture of time

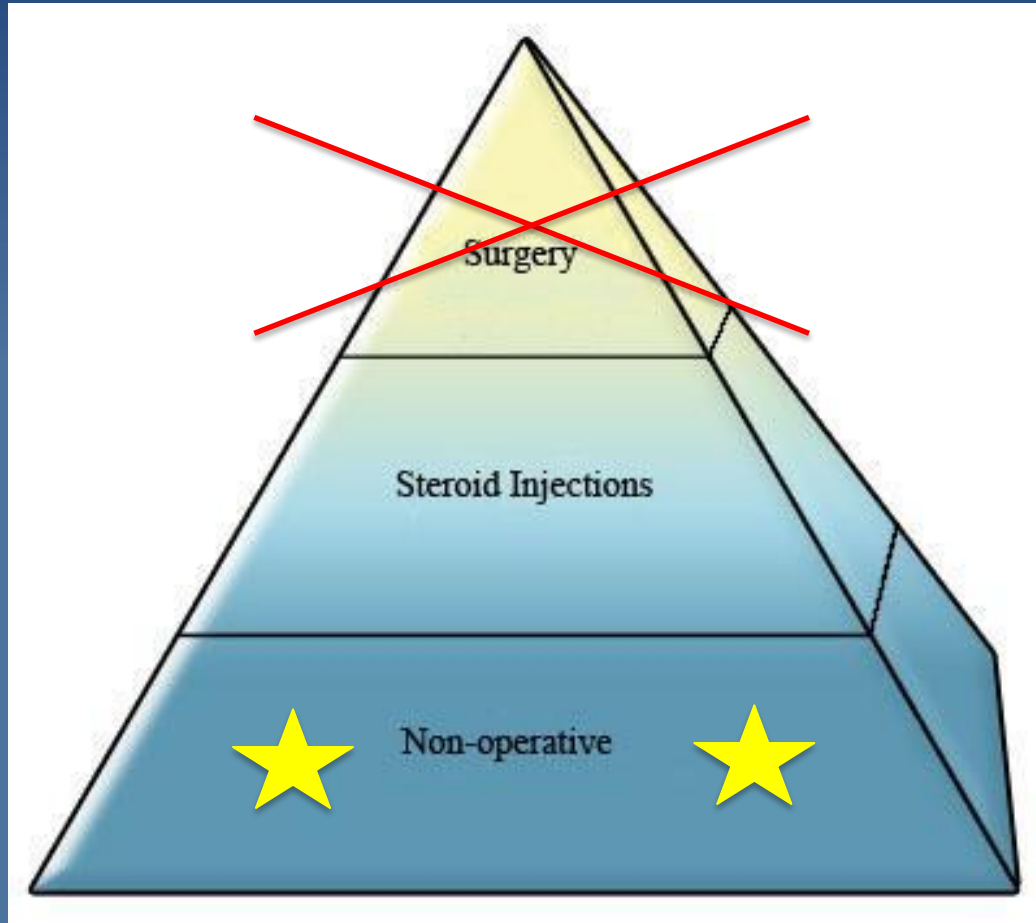
Tier #2 Injections



- Facet injections
- Medial branch blocks
- Neurotomies

Treatment

Degenerative Discs & Facet Arthritis



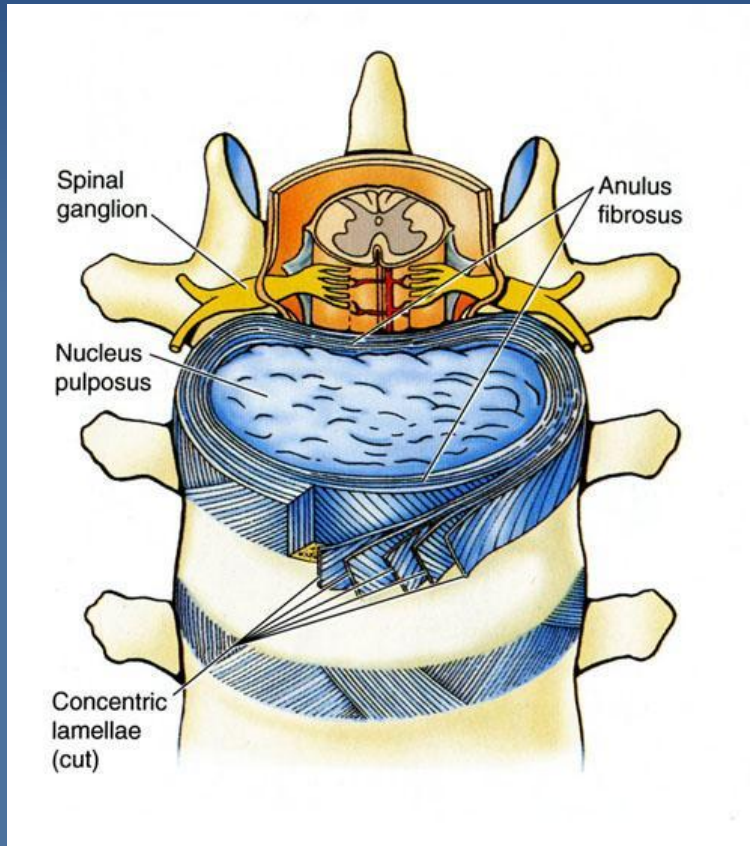
#2

Disc Herniations

Nerve
Compression

Basic Anatomy

Discs- A Jelly Filled Doughnut

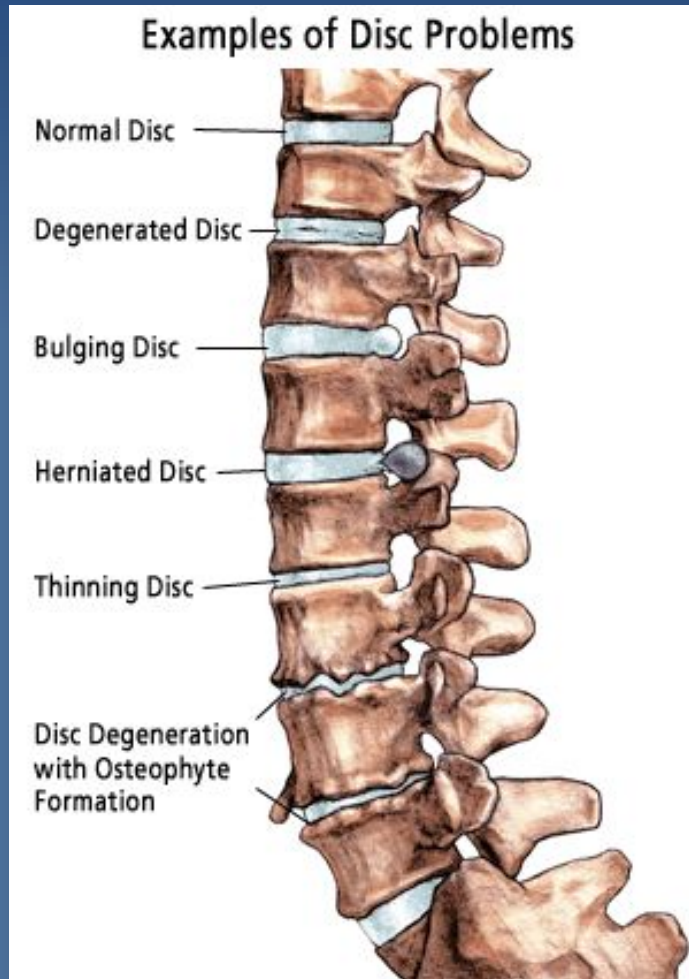


- Dough: Annulus fibrosus
- Jelly: Nucleus pulposus
- 80% water
- 25% of spinal column length
- Tires

Nerve
Compression

Basic Anatomy

Discs- A Jelly Filled Doughnut



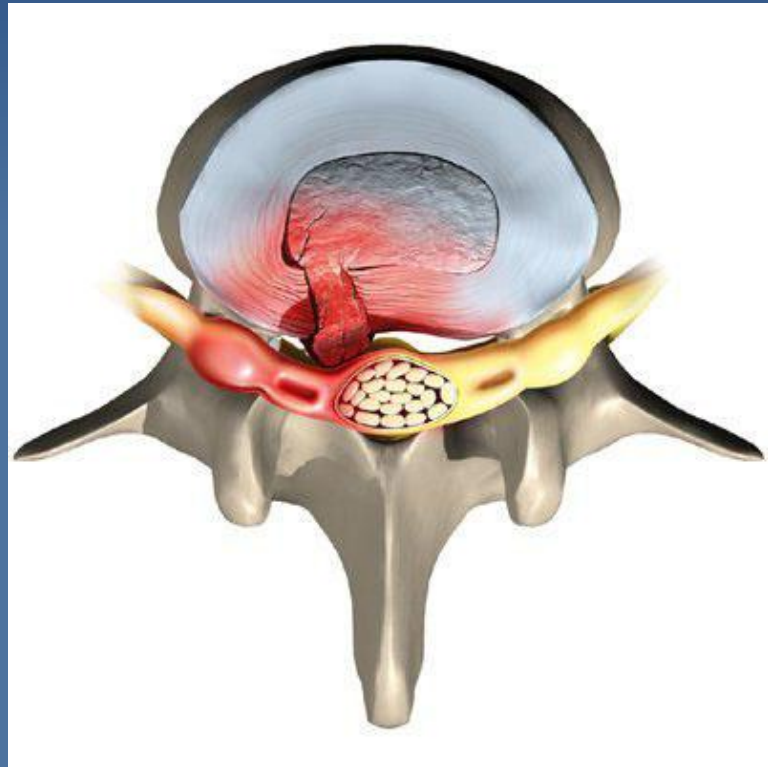
- Dough: Annulus fibrosis
- Jelly: Nucleus pulposus
- 80% water
- 25% of spinal column length
- Tires

Nerve
Compression

Disc Herniations

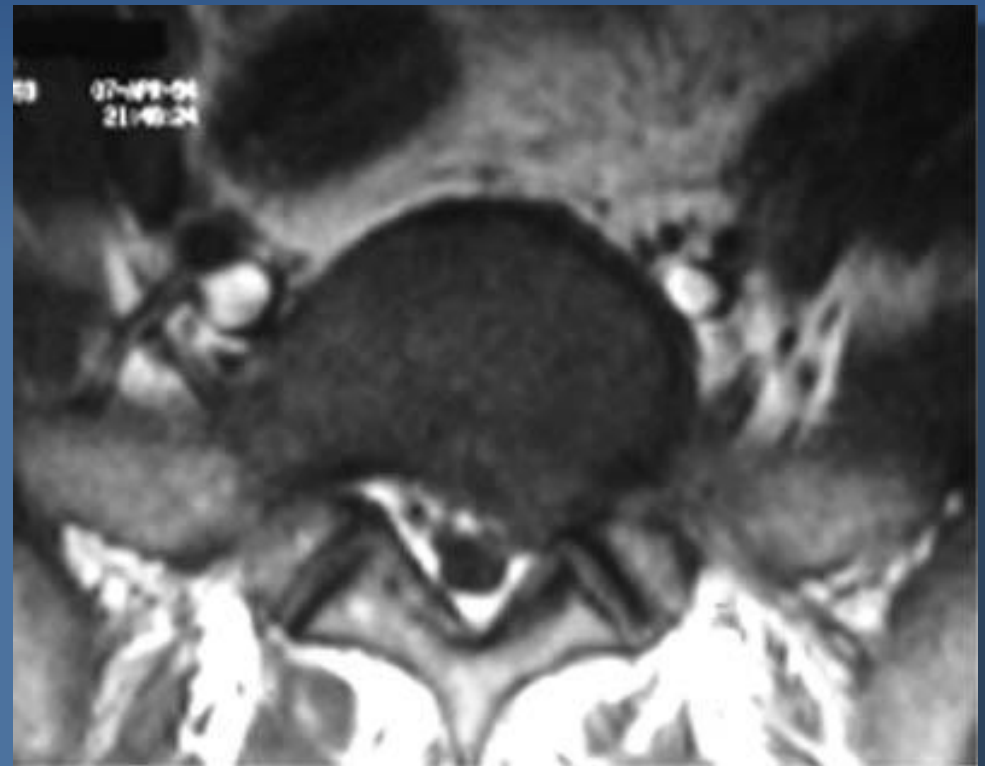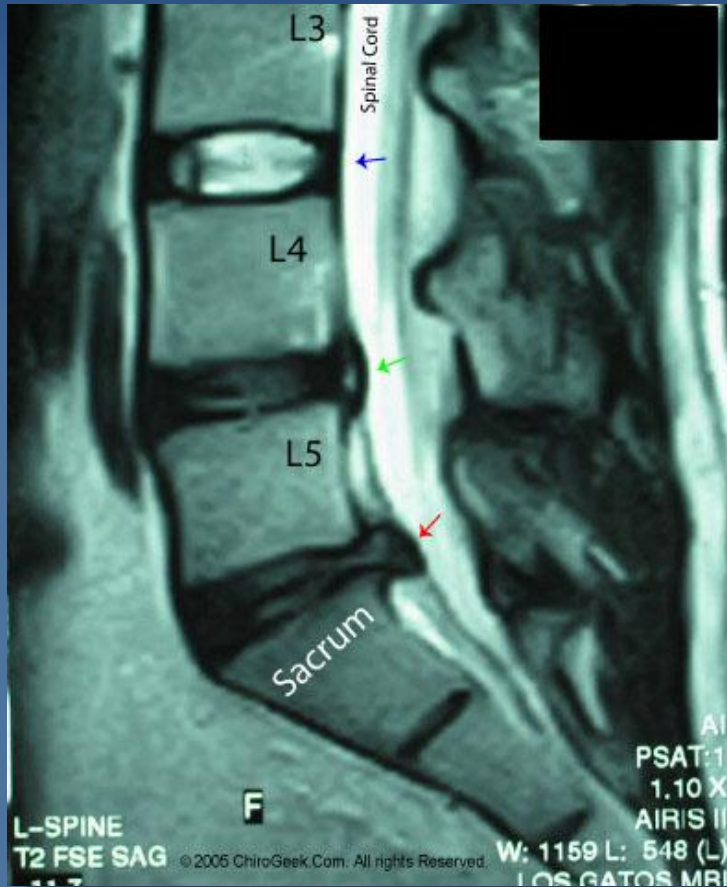Symptoms

- Shoulder/ arm pain
- Buttock/ leg pain (i.e., sciatica)
- Numbness
- Loss of a reflex
- Muscle weakness

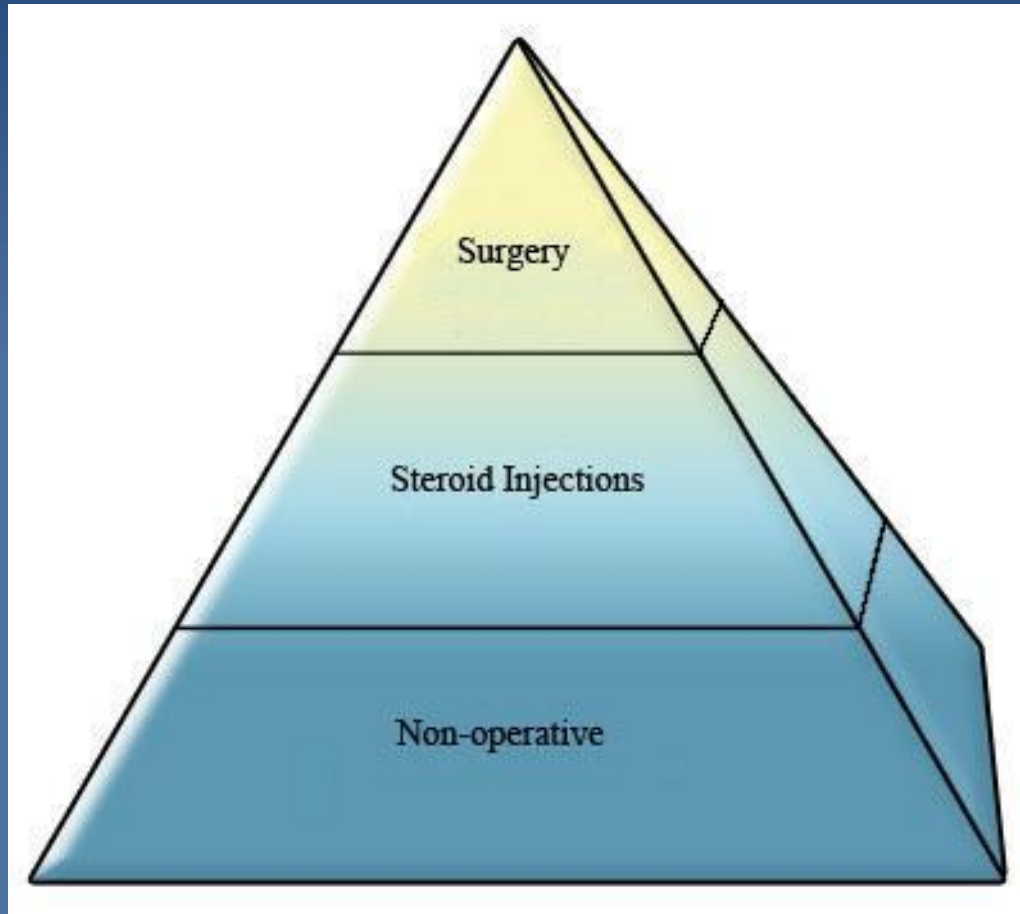


Nerve
Compression

Disc Herniations



Three Tiers of Treatment



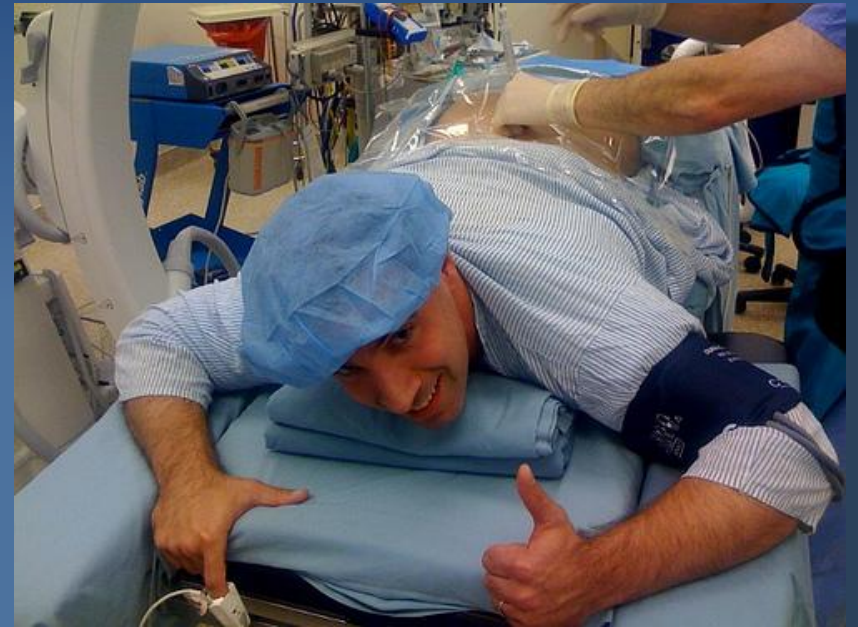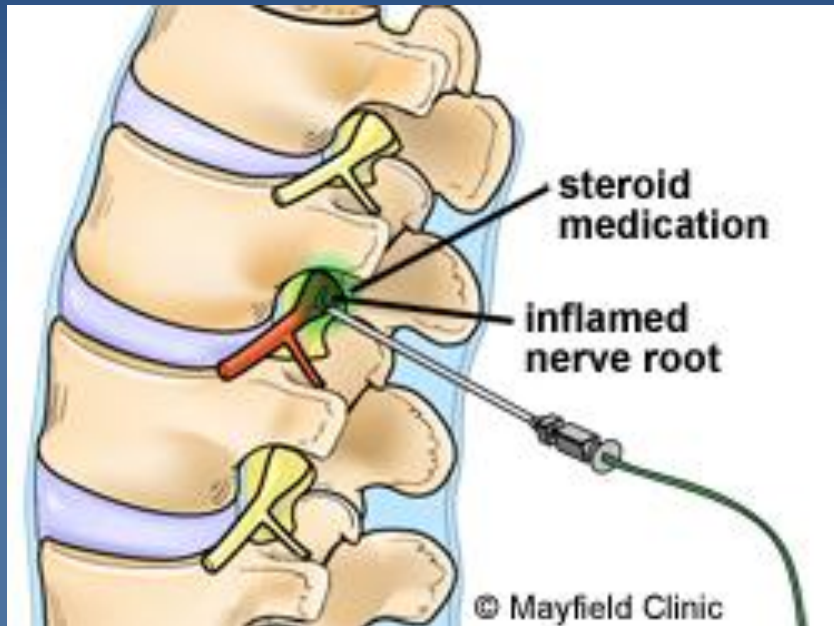
Tier #1

Non-operative Treatment

- Rest/activity modification
- Ice/heat
- NSAID's (limit narcotics)
- Muscle relaxants
- Short course of oral steroids
- Gabapentin
- Physical therapy
- Posture/ergonomics
- Massage
- Acupuncture
- Chiropractic
- Tincture of time

Tier #2

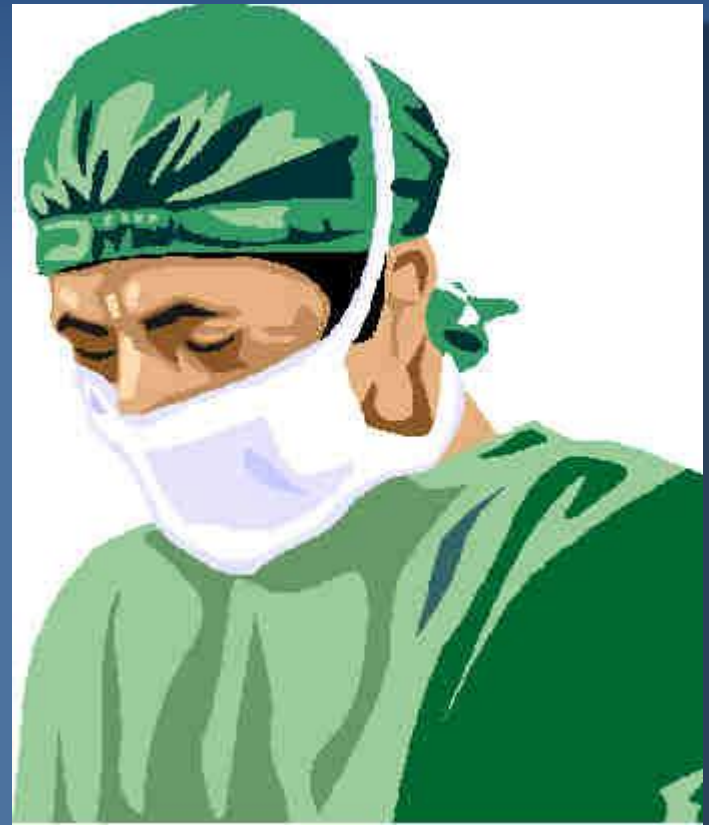Steroid Injections



- Transforaminal steroid injections

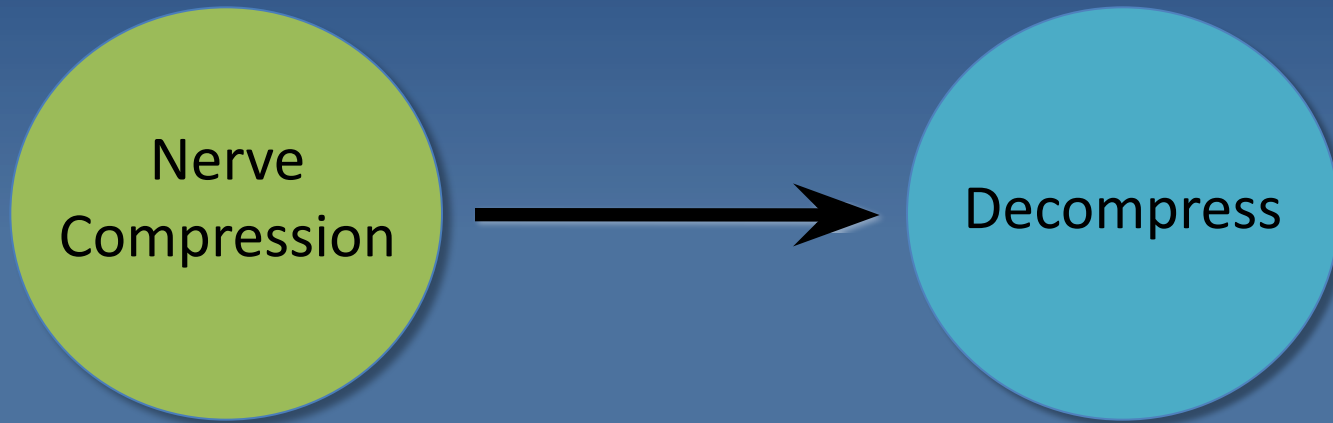
Tier #3 Surgery

- Indications
 - Uncontrolled pain
 - Major or progressive muscle weakness
 - Radiculopathy for 4-6 weeks that has failed conservative treatment
 - Cauda equina
 - Myelopathy



Disc Herniations

Treatment Goal



Treatment is for radicular symptoms, NOT neck or back pain

“A pinched nerve causes radicular symptoms, NOT neck or back pain”

Diagnostic Studies

WARNING!

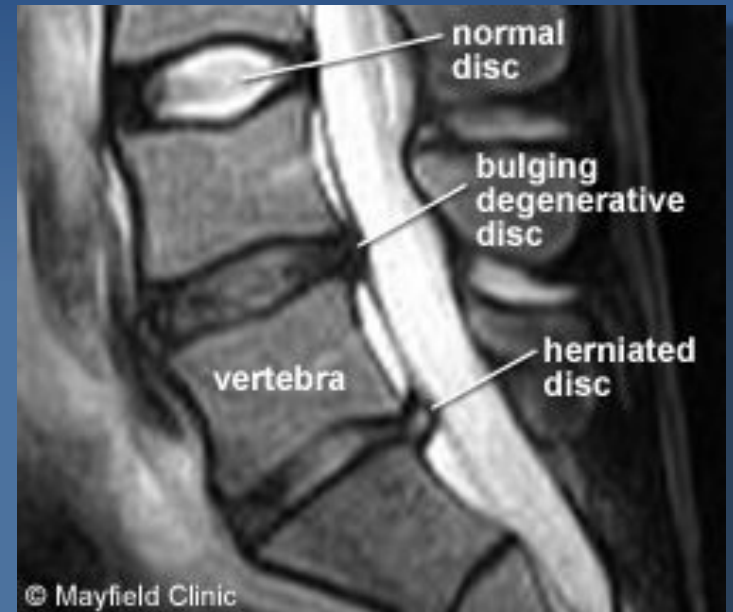- Do not base operative decisions **ONLY** on diagnostic tests
- Correlate test results with the history and physical exam



Imaging- Lumbar Spine

Asymptomatic Patients

- 21% of patients >60 had spinal stenosis
- 36% of patients >60 had a degenerative or herniated disc
- 21% of patients 20-39 years old had a degenerative or herniated disc



Boden et al. Abnormal magnetic-resonance scans of the lumbar spine in asymptomatic subjects. A prospective investigation. The Journal of bone and joint surgery American volume (1990) vol. 72 (3) pp. 403-8

Minimally Invasive Surgery (MIS) for a Disc Herniation

Surgery

Minimally Invasive Techniques

Advantages

- Less soft tissue disruption
- Less blood loss
- Less pain
- Fewer Infections
- Shorter hospitalization recovery times
- Improved visualization with use of a microscope
- Steep learning curve

Disadvantages

Surgery

Minimally Invasive Techniques

Advantages

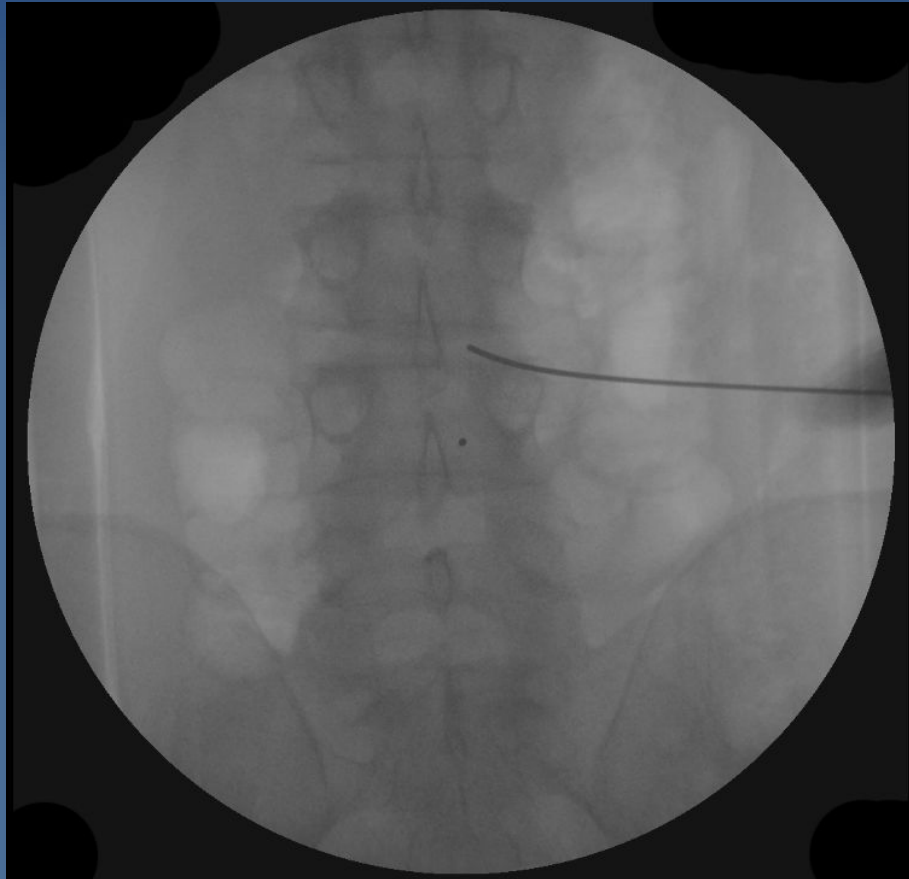
- Less soft tissue disruption
- Less blood loss
- Less pain
- Fewer Infections
- Shorter hospitalization recovery times
- Improved visualization with use of a microscope
- Steep learning curve

Disadvantages

Nerve
Compression

Surgery

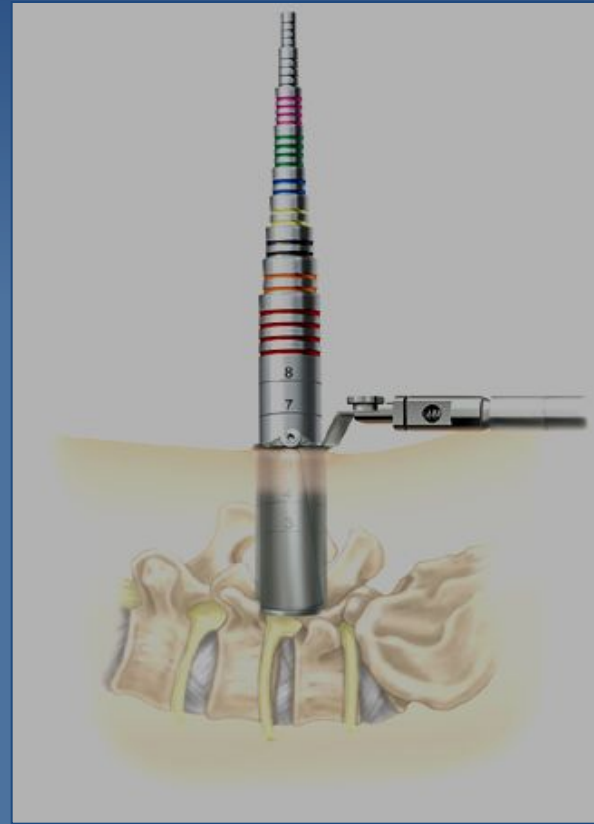
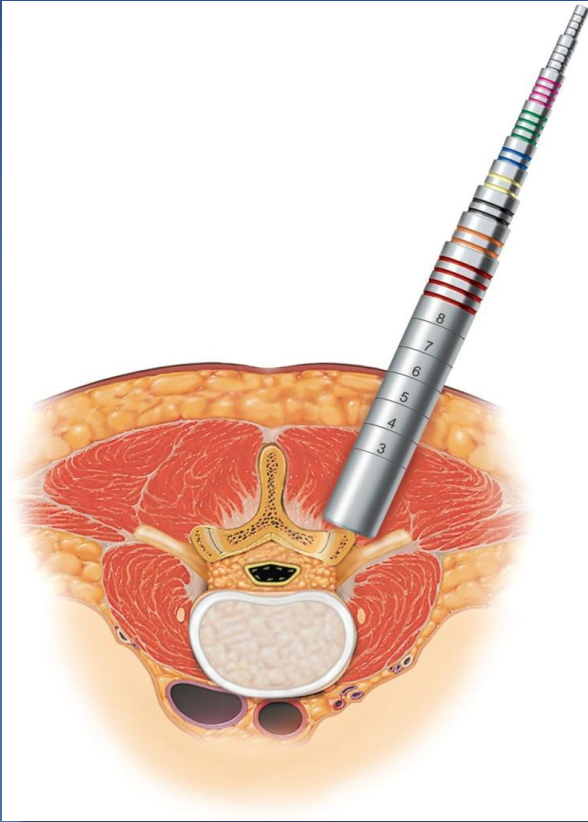
Minimally Invasive Decompression



Nerve
Compression

Surgery

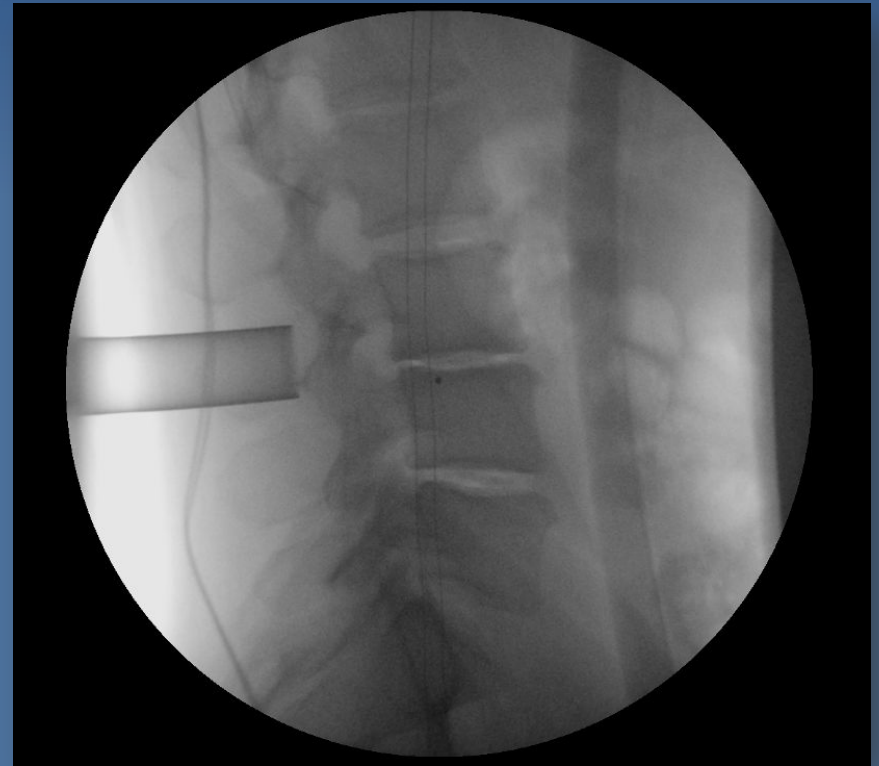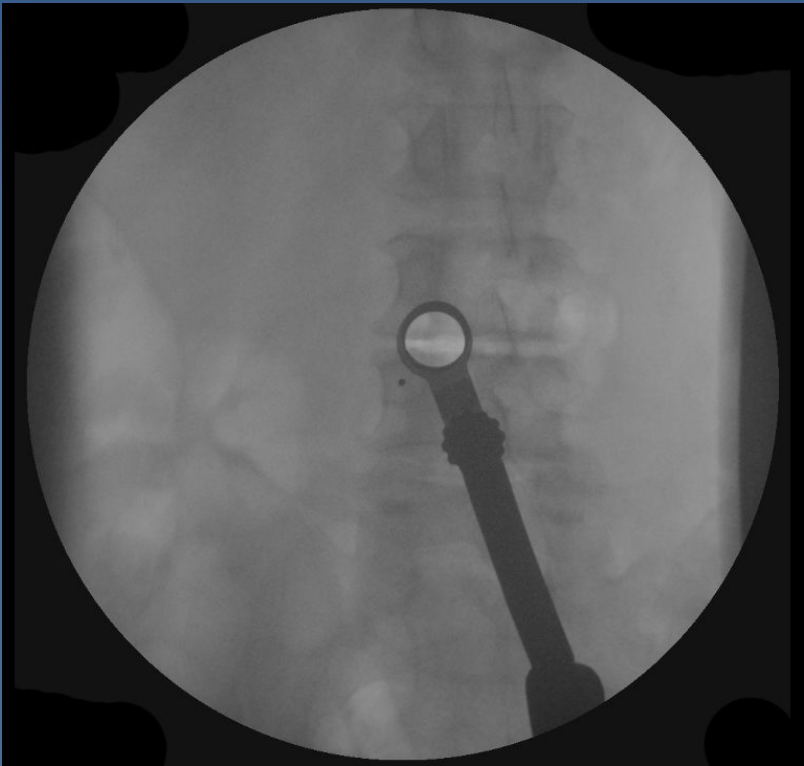
Minimally Invasive Decompression



Nerve
Compression

Surgery

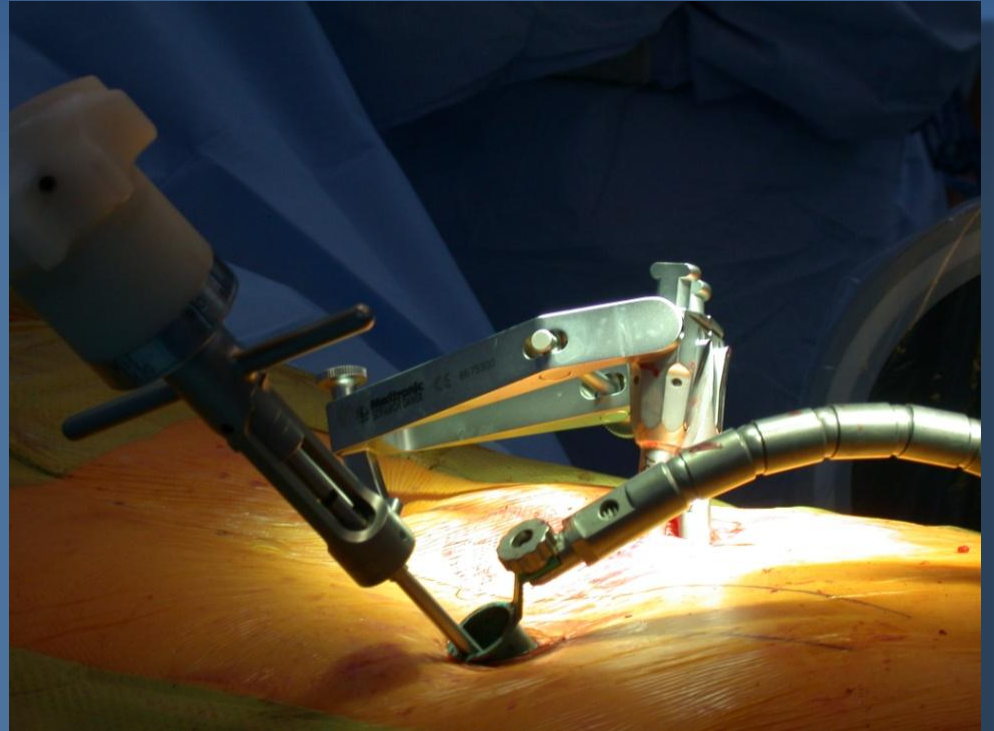
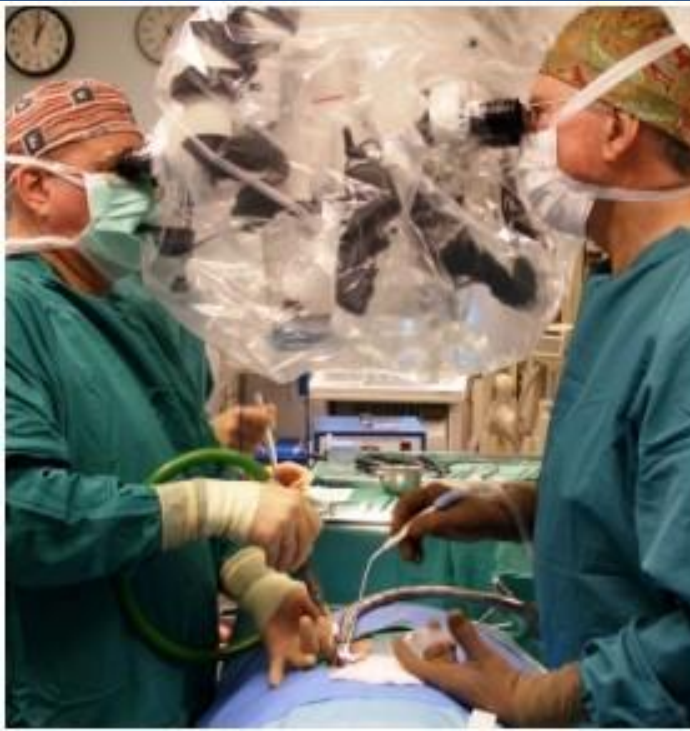Minimally Invasive Decompression



Nerve
Compression

Surgery

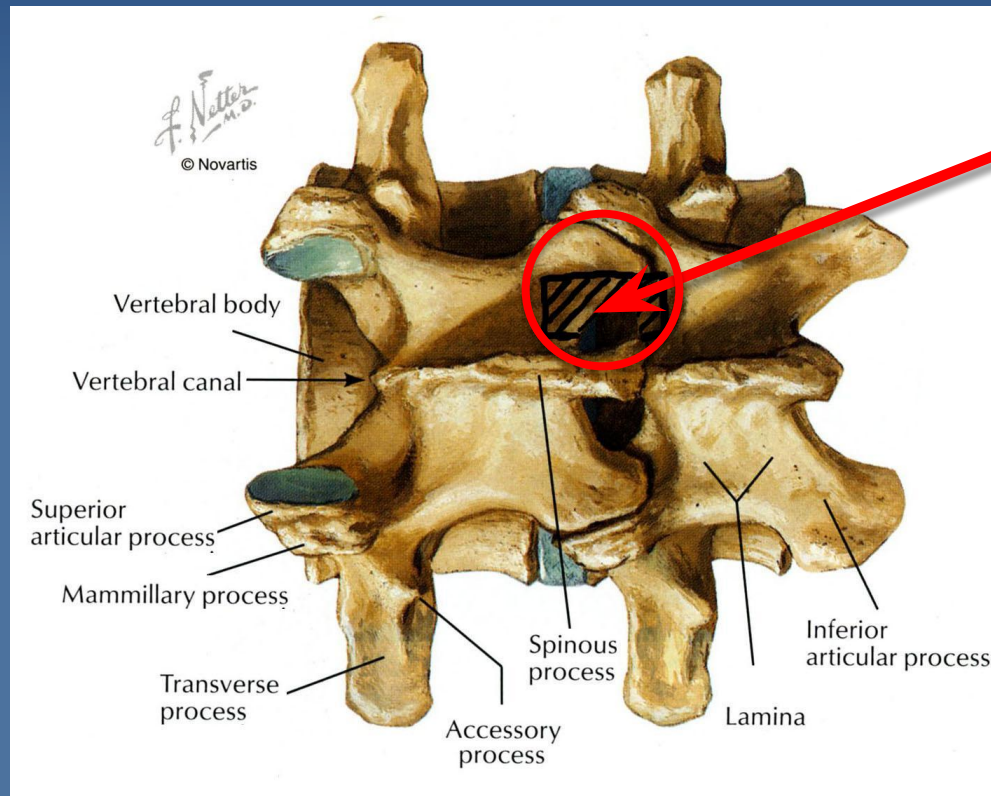
Minimally Invasive Decompression



Nerve
Compression

Surgery

Minimally Invasive Decompression

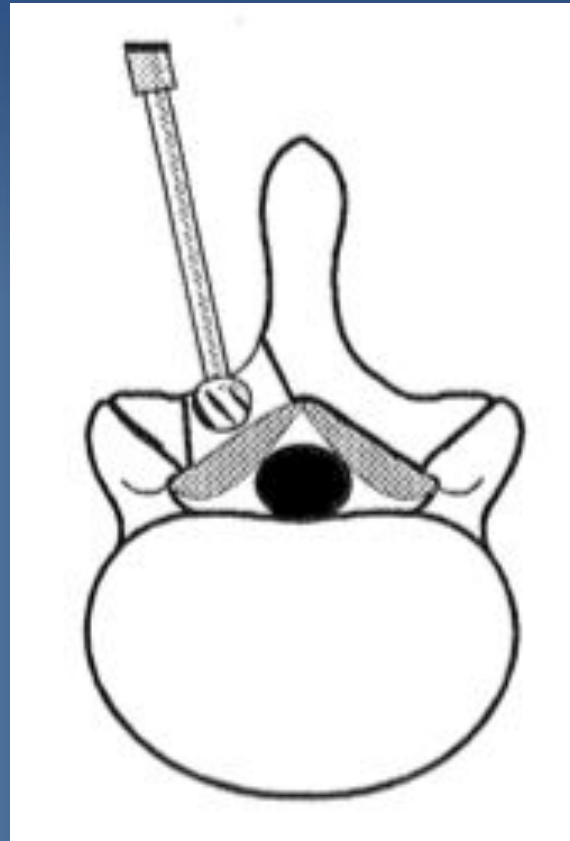


Laminotomy

Nerve
Compression

Surgery

Minimally Invasive Decompression



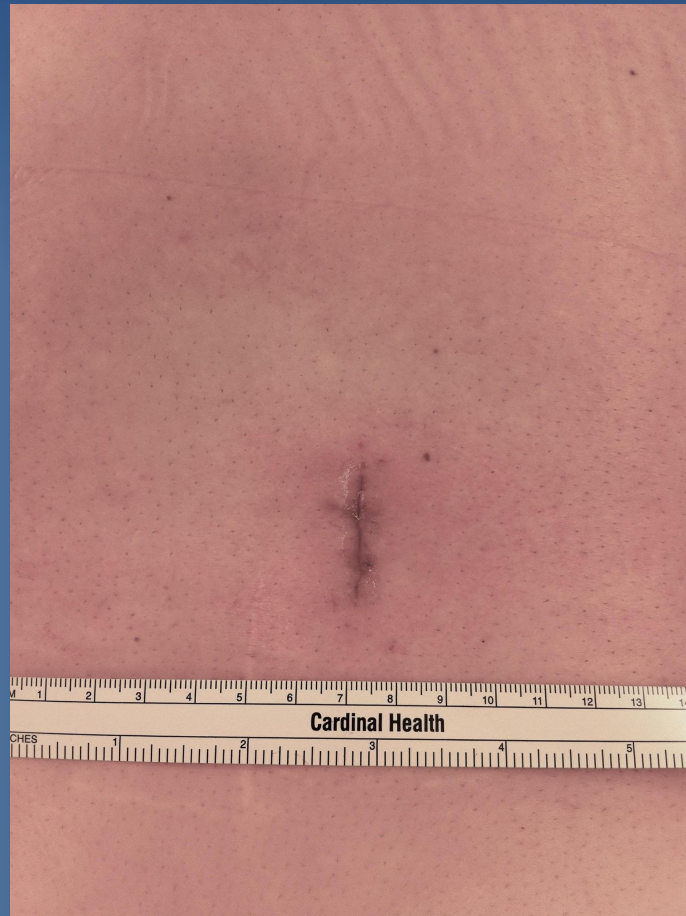
Nerve
Compression

Surgery

Minimally Invasive Decompression



18 mm



#3

Spinal Stenosis

Nerve
Compression

Spinal Stenosis

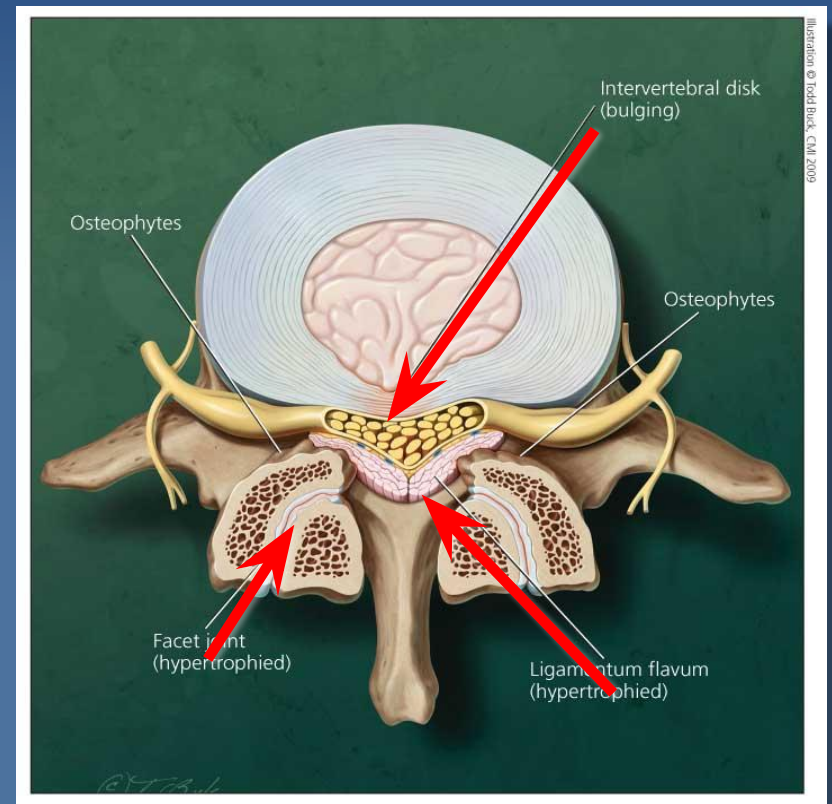
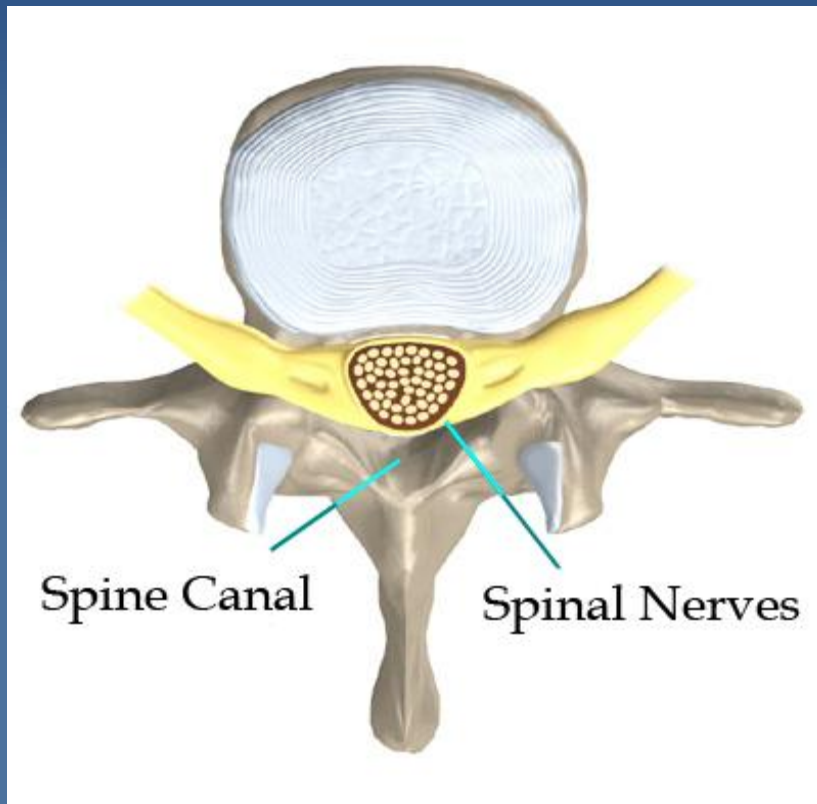
Definition

- Stenosis (στένωσις)= “narrowing” from Ancient Greek
- Narrowing of the spinal canal which can cause nerve compression.

Nerve
Compression

Spinal Stenosis

Central vs. Foraminal

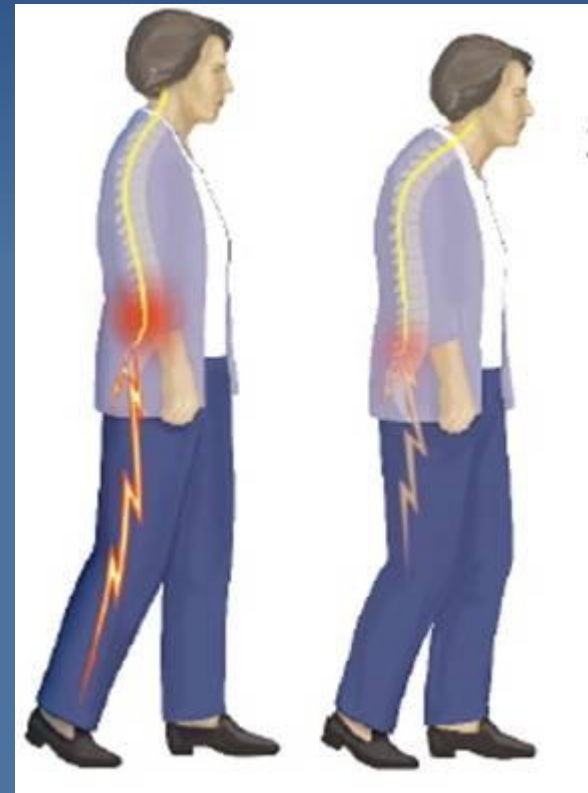

Nerve
Compression

Spinal Stenosis

Neurogenic Claudication

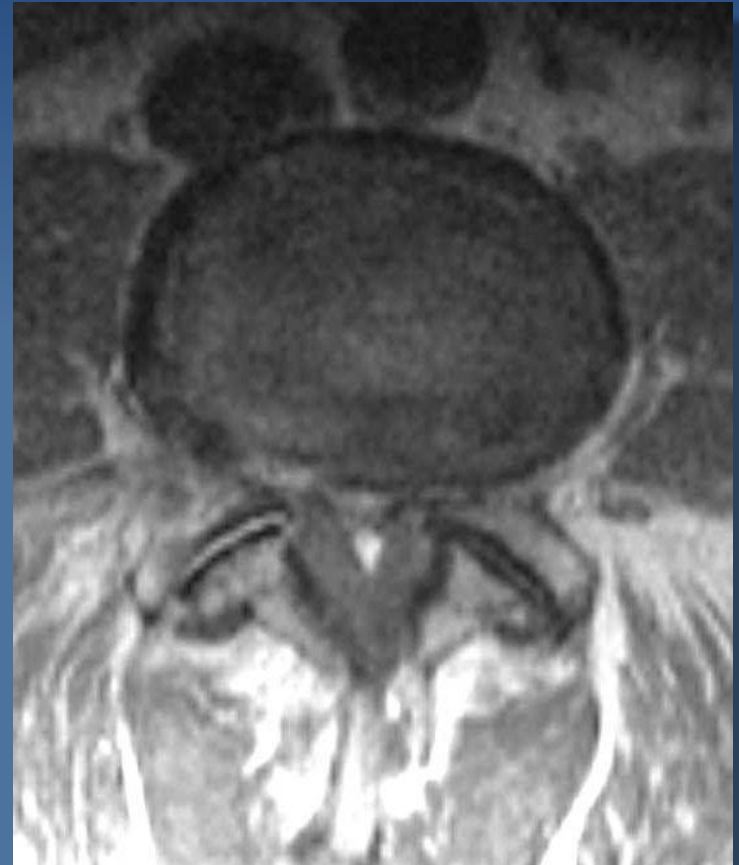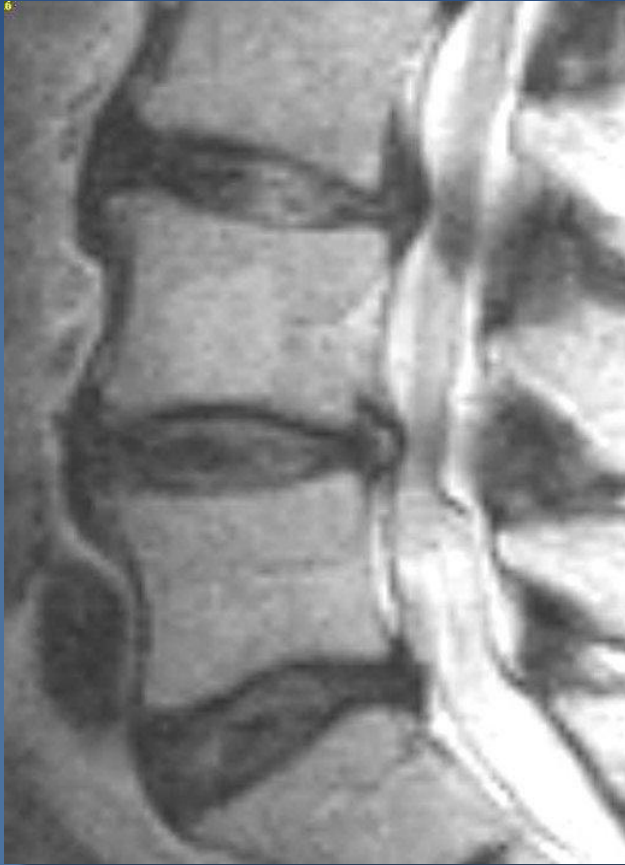- Pain, tingling, numbness, and weakness in the buttocks and back of the legs
- Heavy legs
- Difficulty walking distances
- Bending forward makes it better



Nerve
Compression

Spinal Stenosis

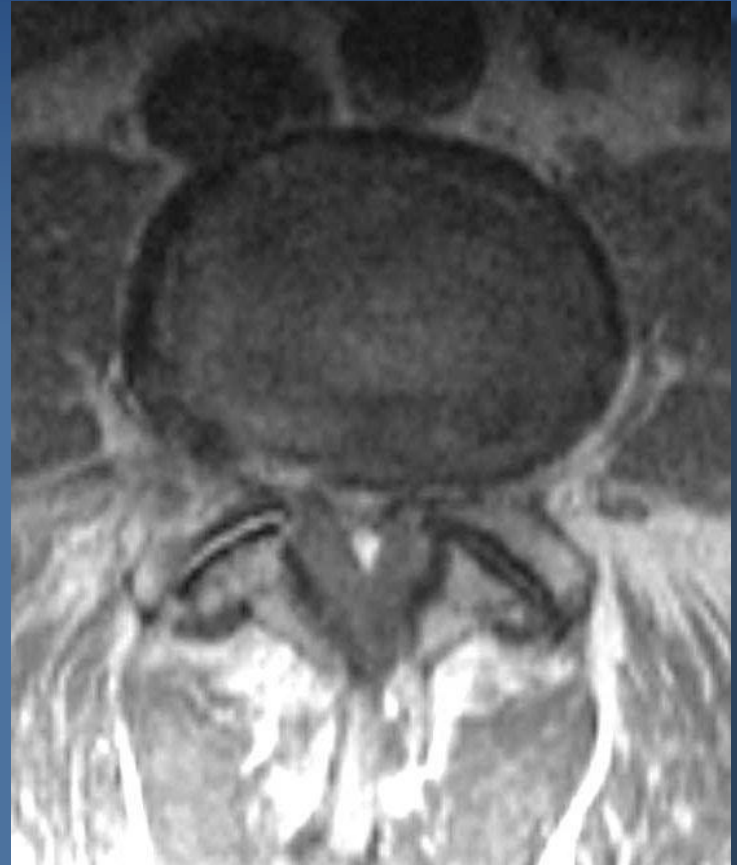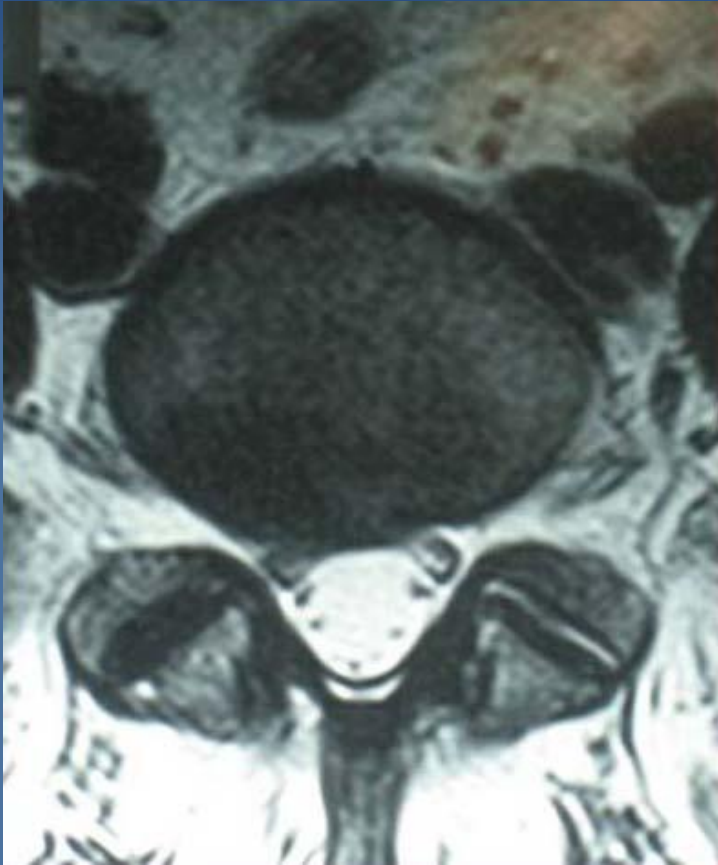Neurogenic Claudication



Nerve
Compression

Spinal Stenosis

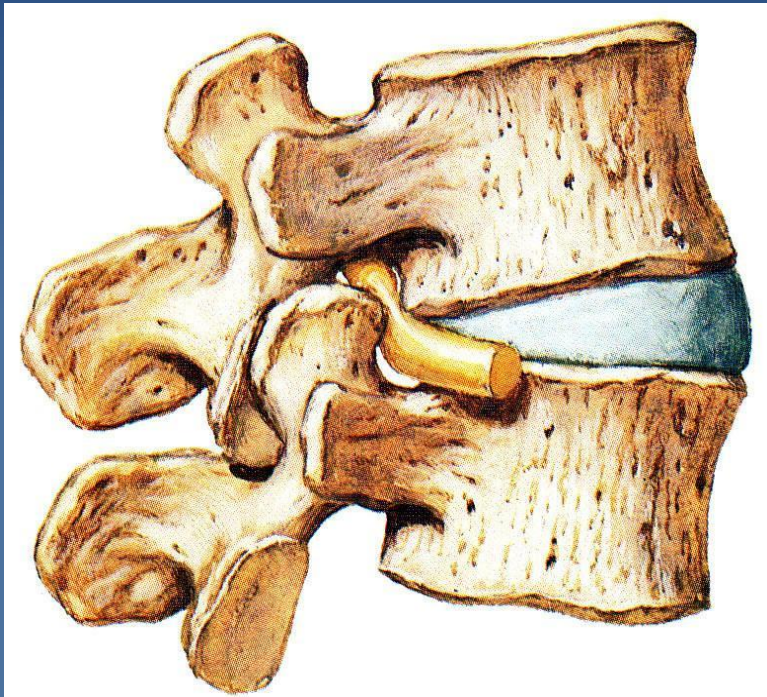
Neurogenic Claudication



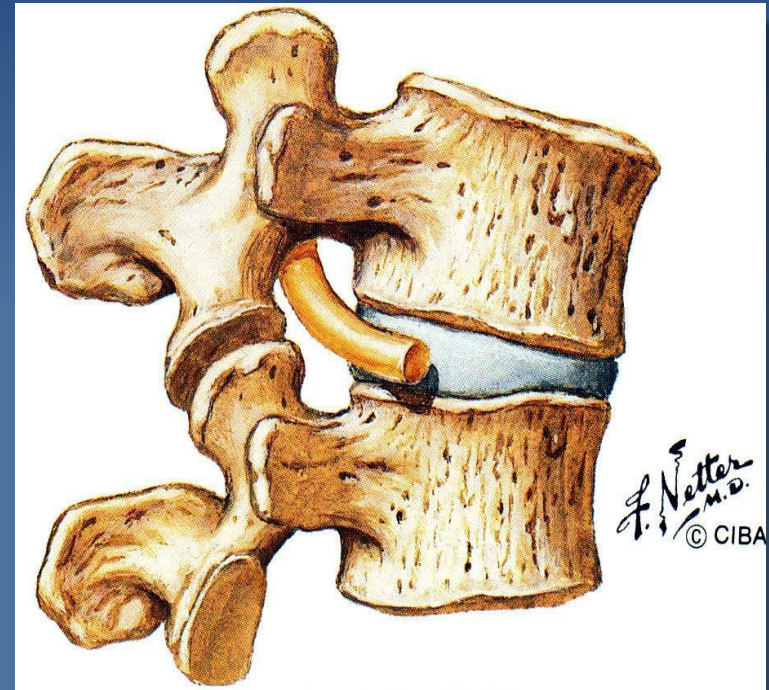
Nerve
Compression

Spinal Stenosis

Foraminal Stenosis



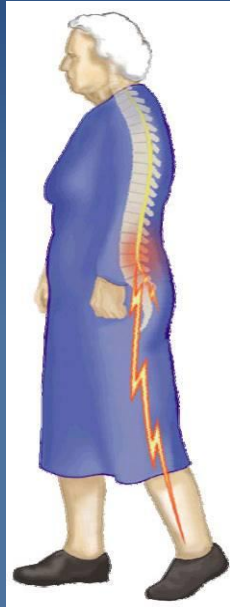Equivalent to standing
or walking



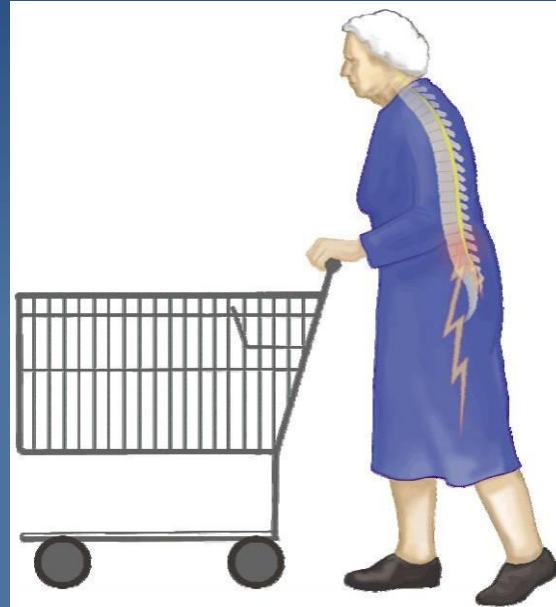Equivalent to sitting or
bending forward

Nerve Compression

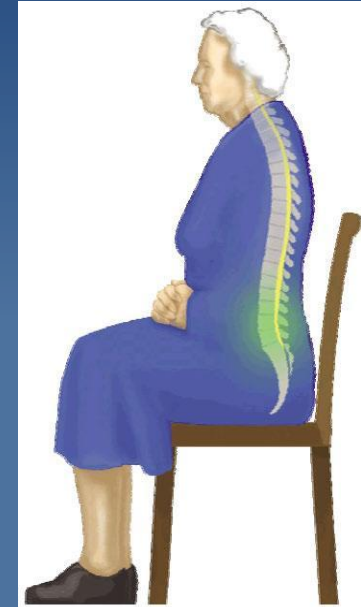
Spinal Stenosis



- Standing/ walking provoke symptoms
 - Leg pain
 - Leg weakness

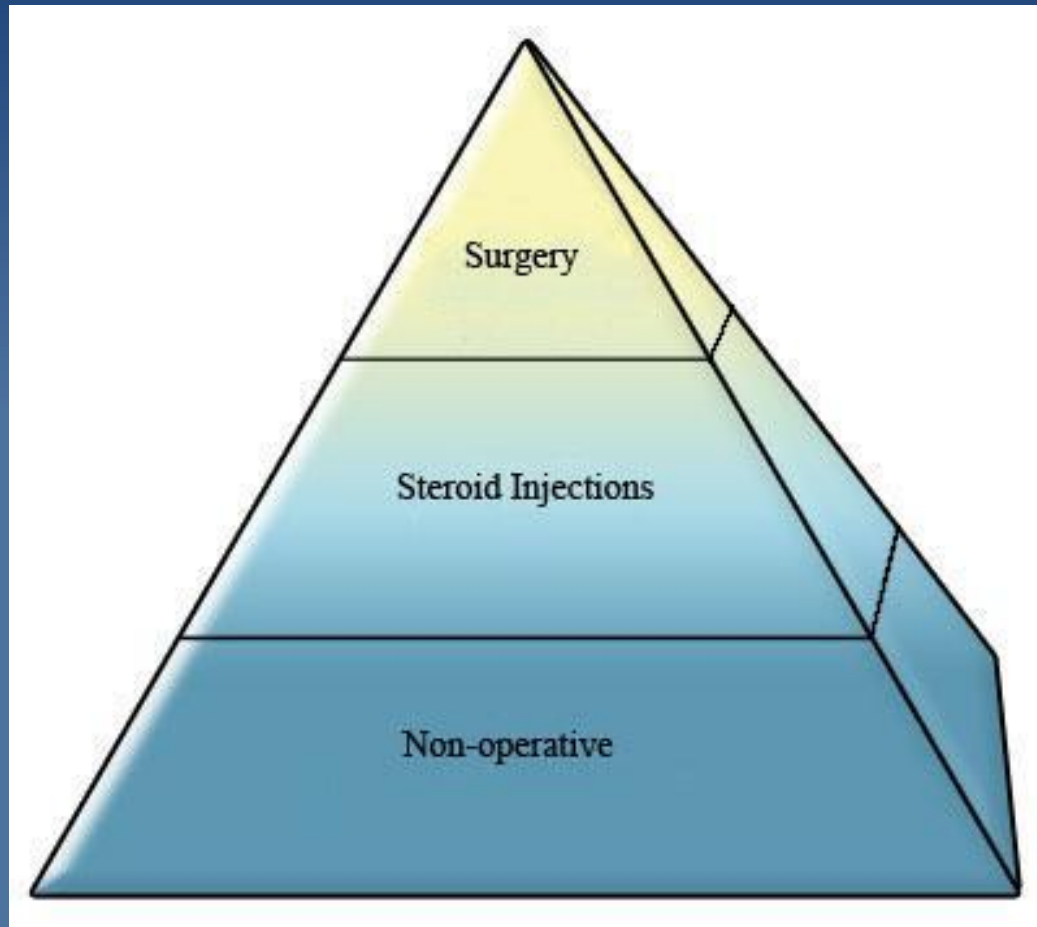


- “Shopping cart sign”
Patients lean forward to decrease pain



- Sitting relieves symptoms

Three Tiers of Treatment



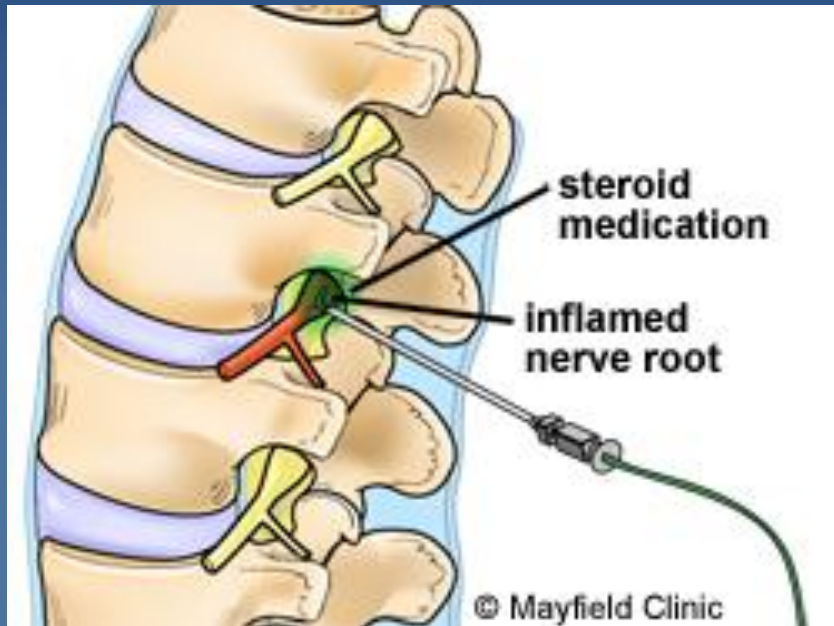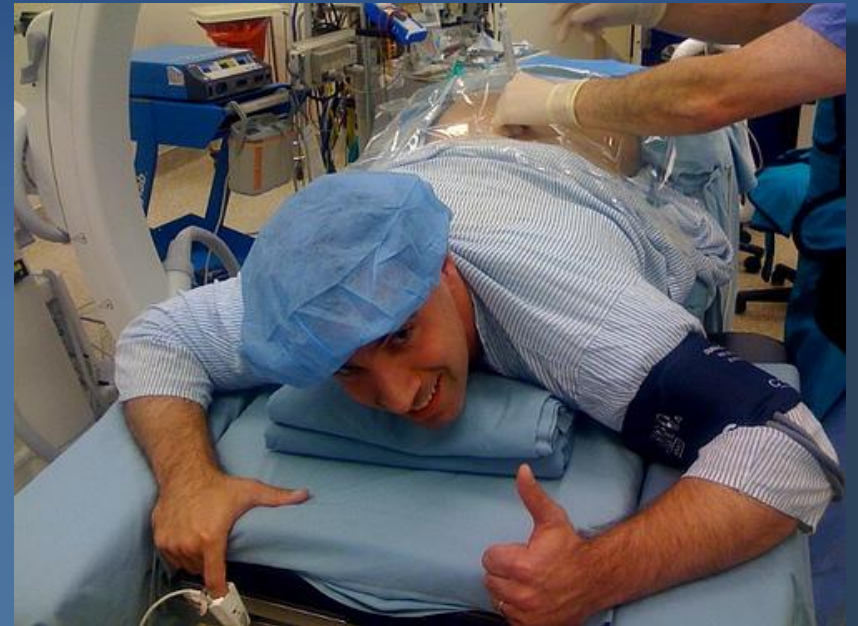
Tier #1

Non-operative Treatment

- Rest/activity modification
- Ice/heat
- NSAID's (limit narcotics)
- Muscle relaxants
- Short course of oral steroids
- Gabapentin
- Physical therapy
- Posture/ergonomics
- Massage
- Acupuncture
- Chiropractic
- Tincture of time

Tier #2

Steroid Injections

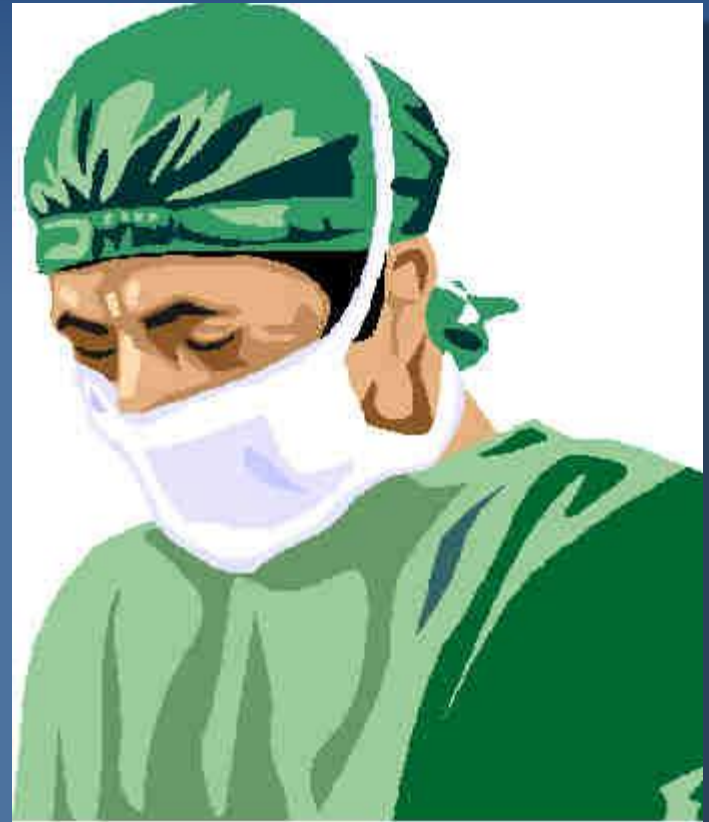

- Steroid injections

Tier #3

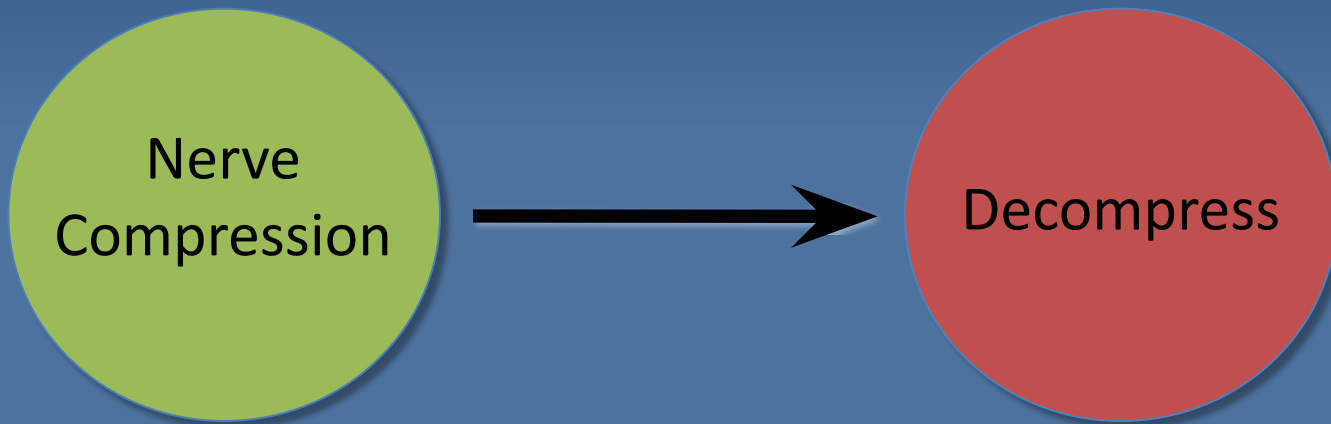
Surgery

- Indications
 - Uncontrolled pain
 - Major or progressive muscle weakness
 - Radiculopathy for 4-6 weeks that has failed conservative treatment
 - Cauda equina
 - Myelopathy



Spinal Stenosis

Treatment



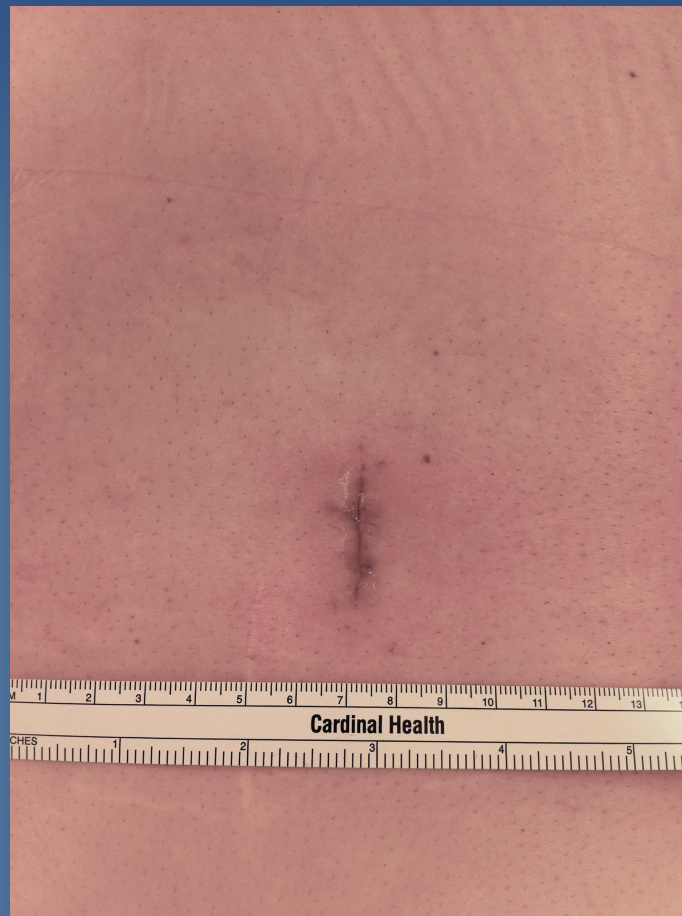
Nerve
Compression

Operative Treatment

Minimally Invasive Decompression



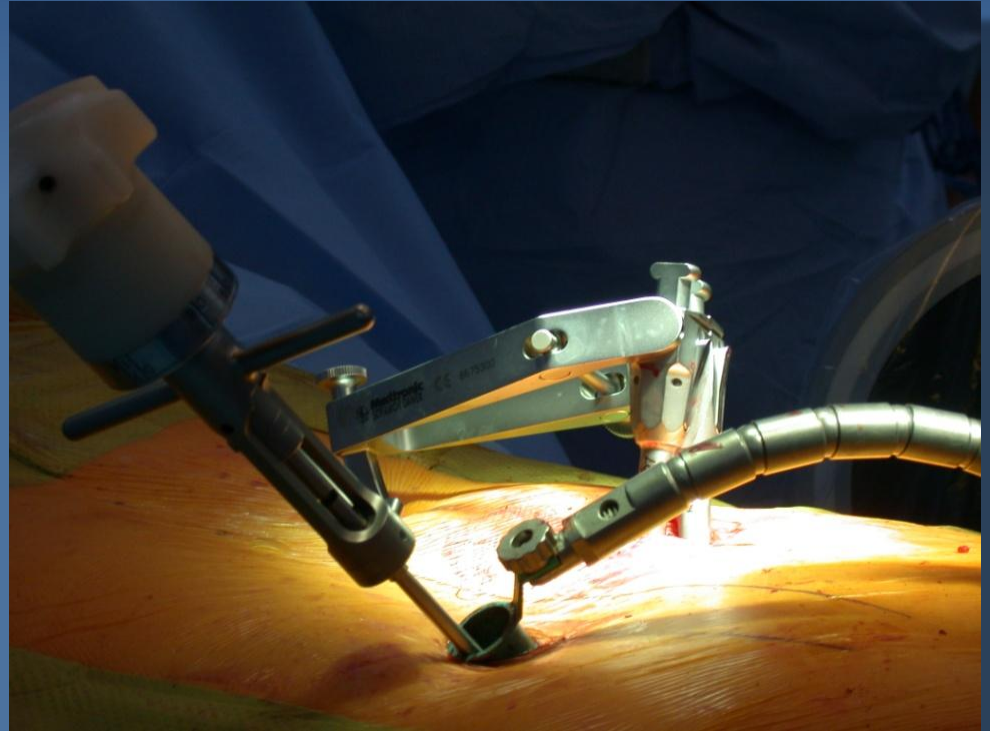
18 mm



Nerve
Compression

Operative Treatment

Minimally Invasive Decompression

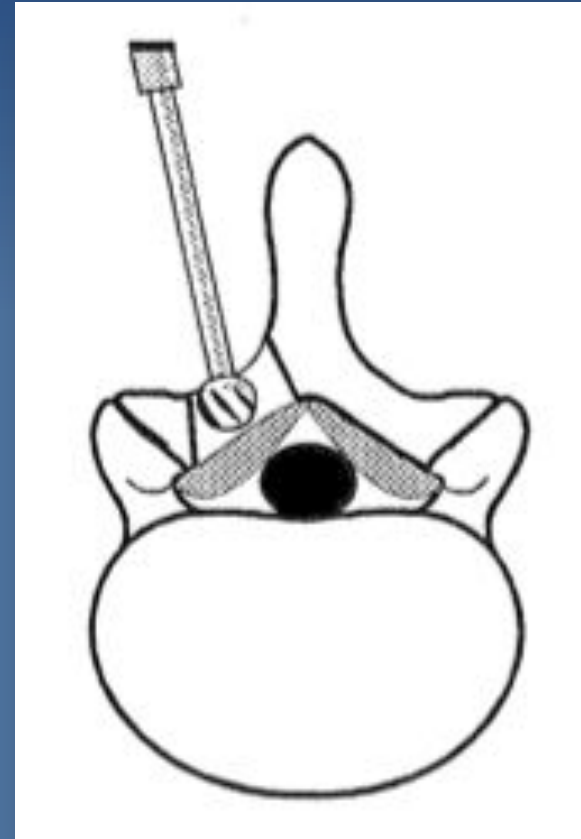
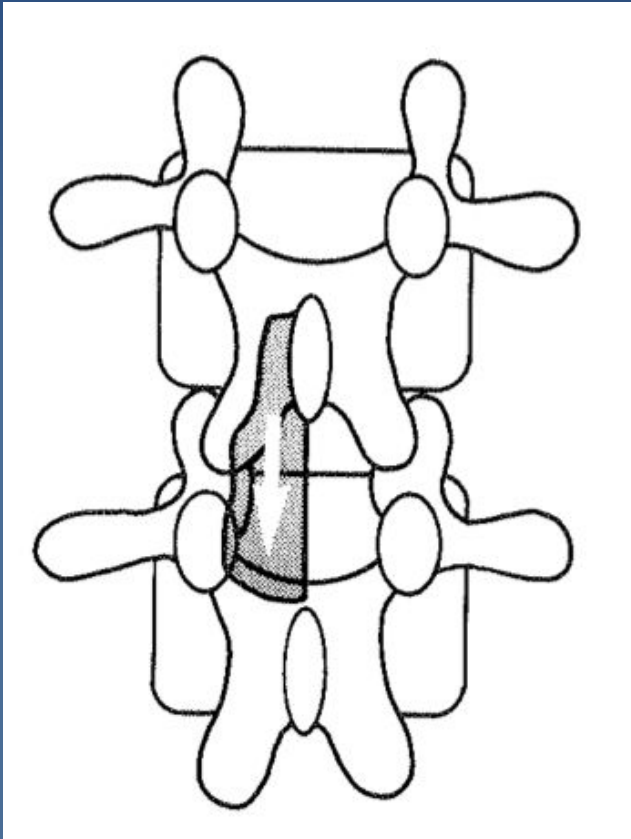


Central

Spinal Stenosis

Treatment- Central Zone

Decompress

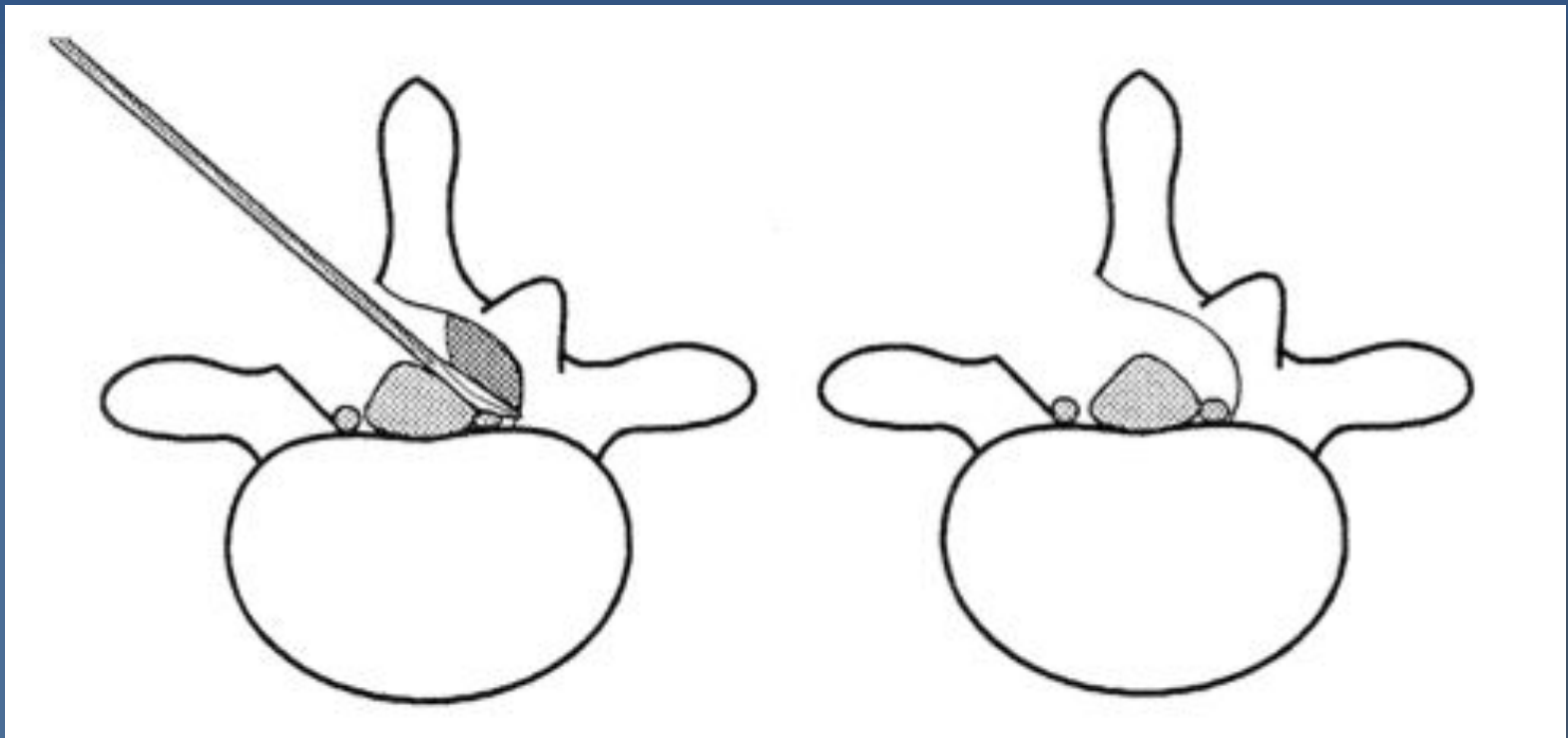


Central

Spinal Stenosis

Treatment- Central Zone

Decompress



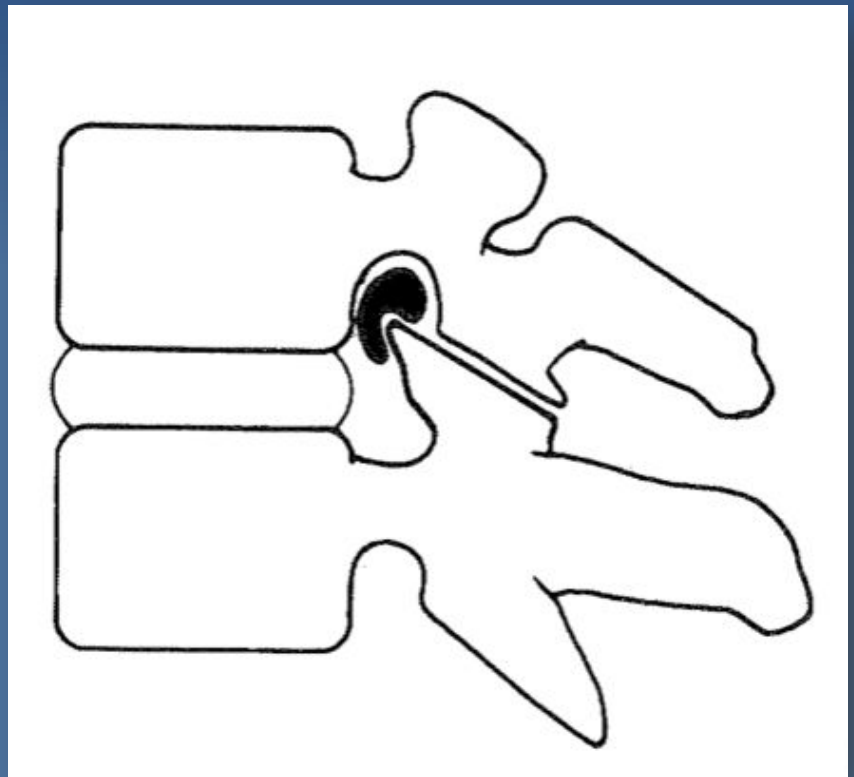
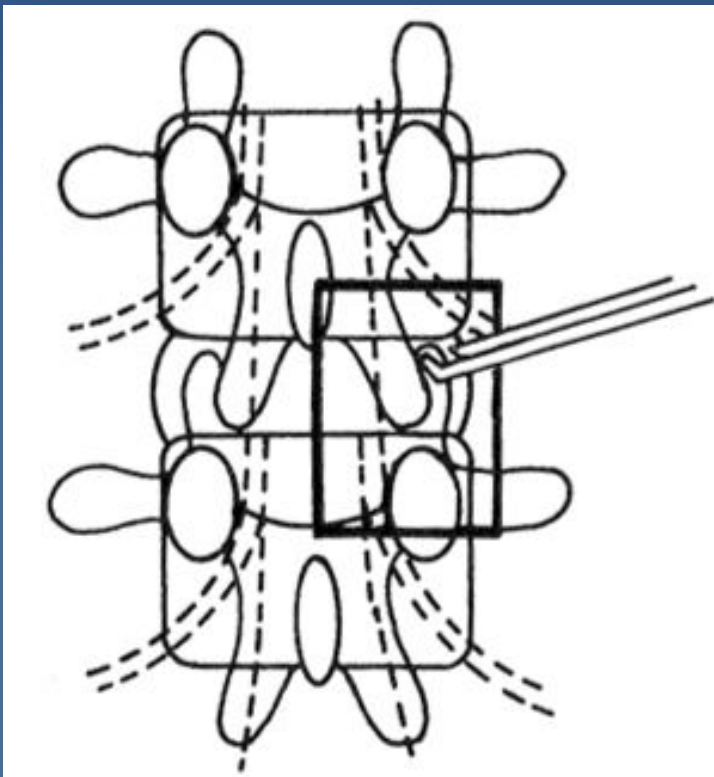
McCulloch J, Young P. Essentials of Spinal Microsurgery. Philadelphia: Lippincott-Raven, 1998.

Foraminal

Spinal Stenosis

Treatment- Foraminal Zone

Decompress



#4

Spondylolisthesis

Hyper-mobility

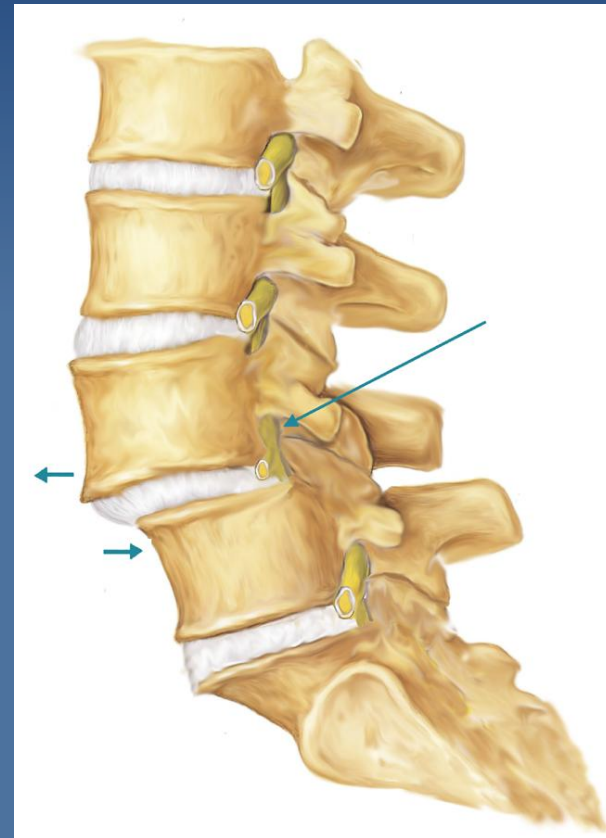
#4 Spondylolisthesis

Nerve Compression

Spondylo = spine

Listhesis= slippage

“The slippage of one vertebra on another”



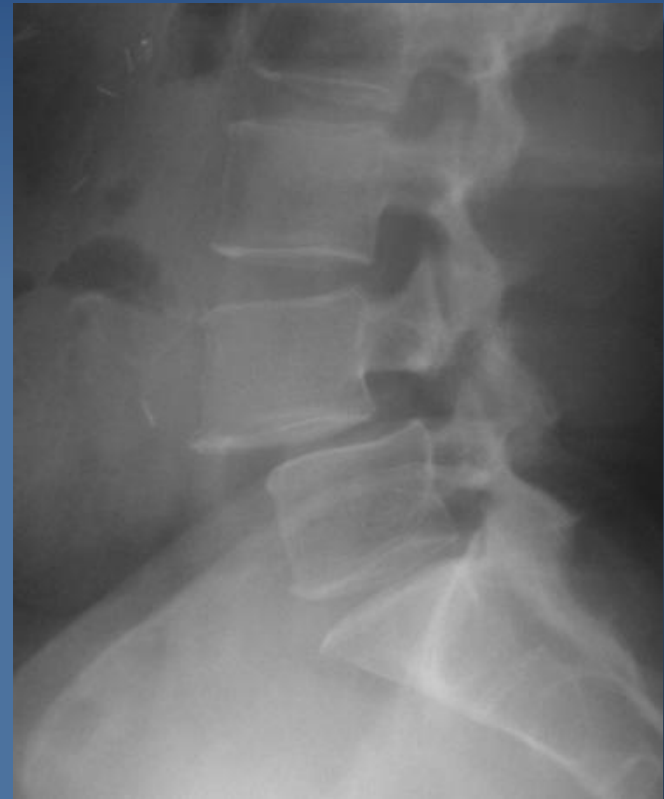Hyper-mobility

#4 Spondylolisthesis

Nerve
Compression

Symptoms

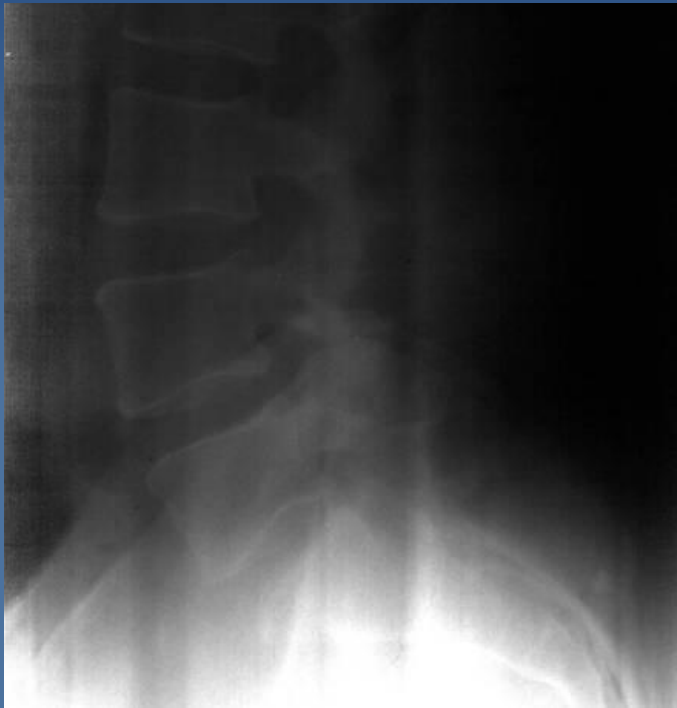- Neck, shoulder, arm pain
- Back, buttock, leg pain
- Numbness, tingling, weakness or loss of reflex in arm or leg
- Can be asymptomatic



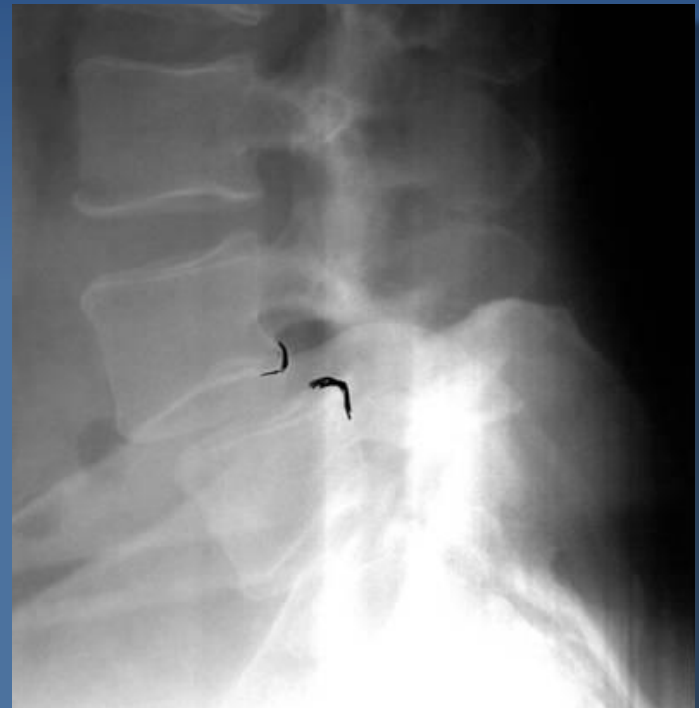Hyper-mobility

#4 Spondylolisthesis

Nerve
Compression

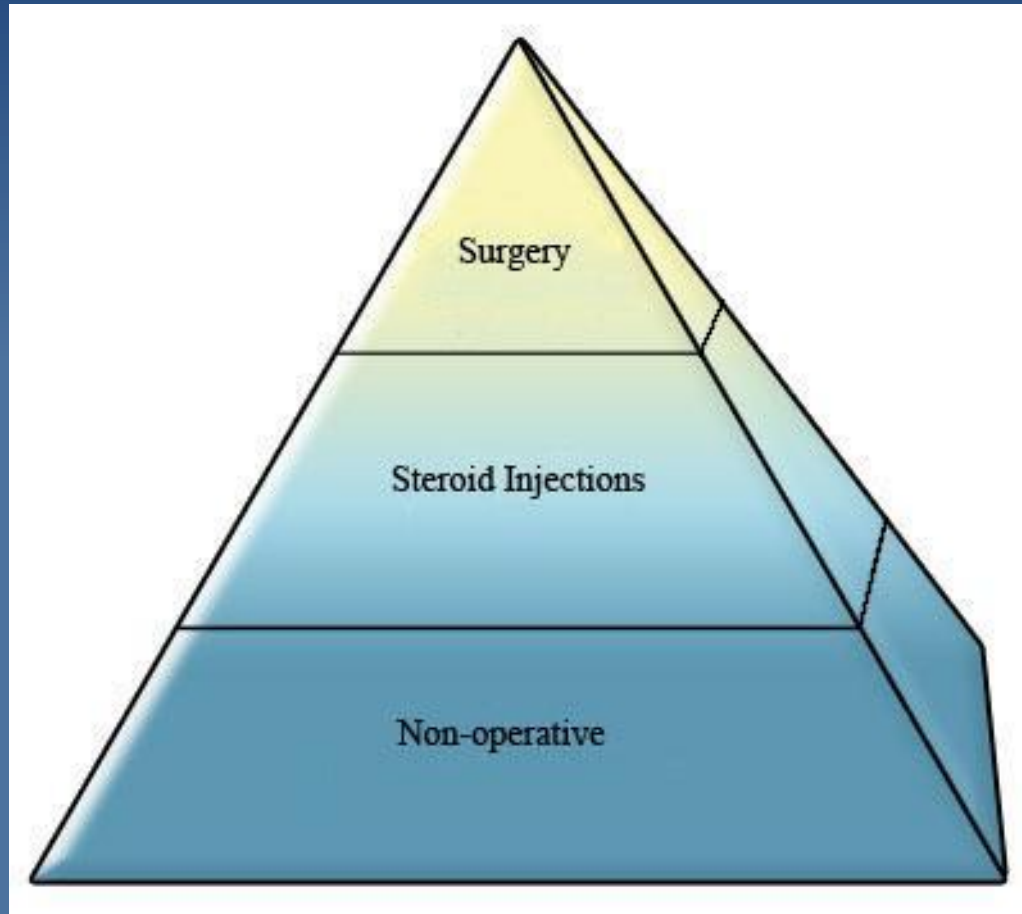


Patient laying on their back



Patient Standing

Three Tiers of Treatment



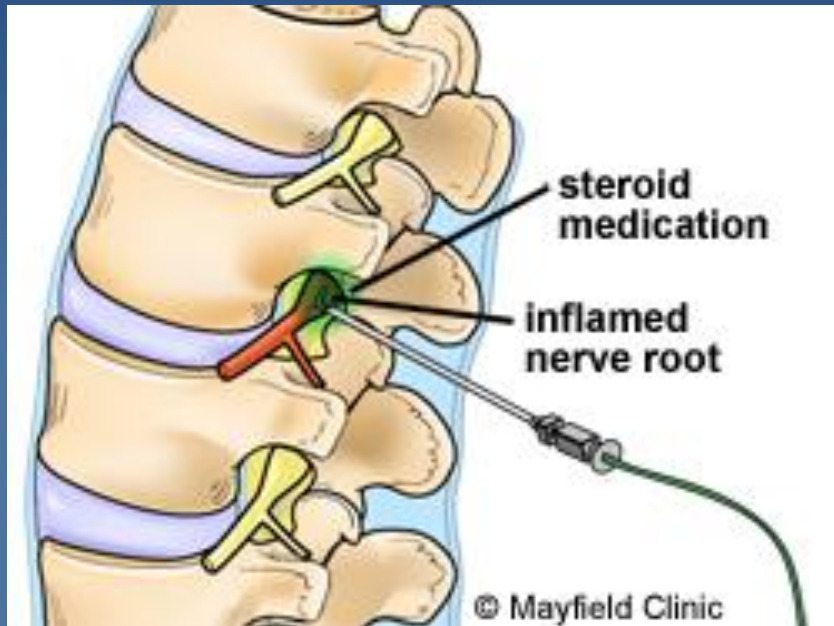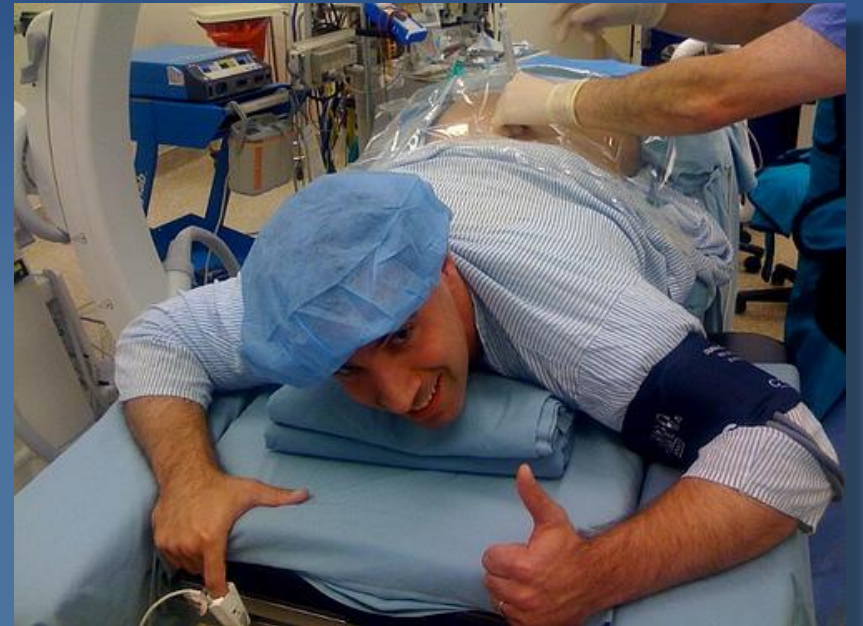
Tier #1

Non-operative Treatment

- Rest/activity modification
- Ice/heat
- NSAID's (limit narcotics)
- Muscle relaxants
- Short course of oral steroids
- Gabapentin
- Weight loss
- Physical therapy
- Posture/ergonomics
- Massage
- Acupuncture
- Chiropractic
- Tincture of time

Tier #2

Steroid Injections

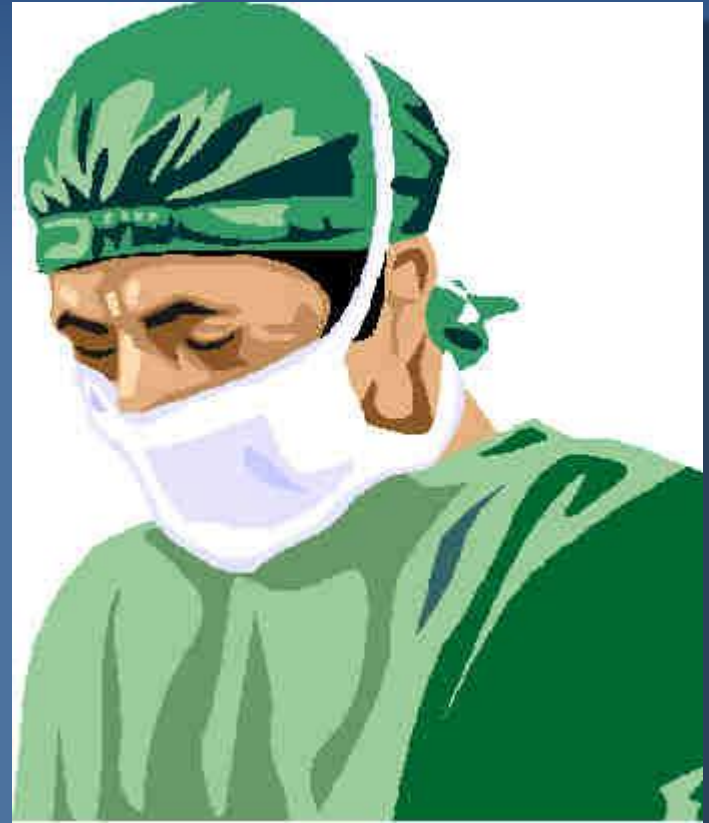

- Steroid injections

Tier #3

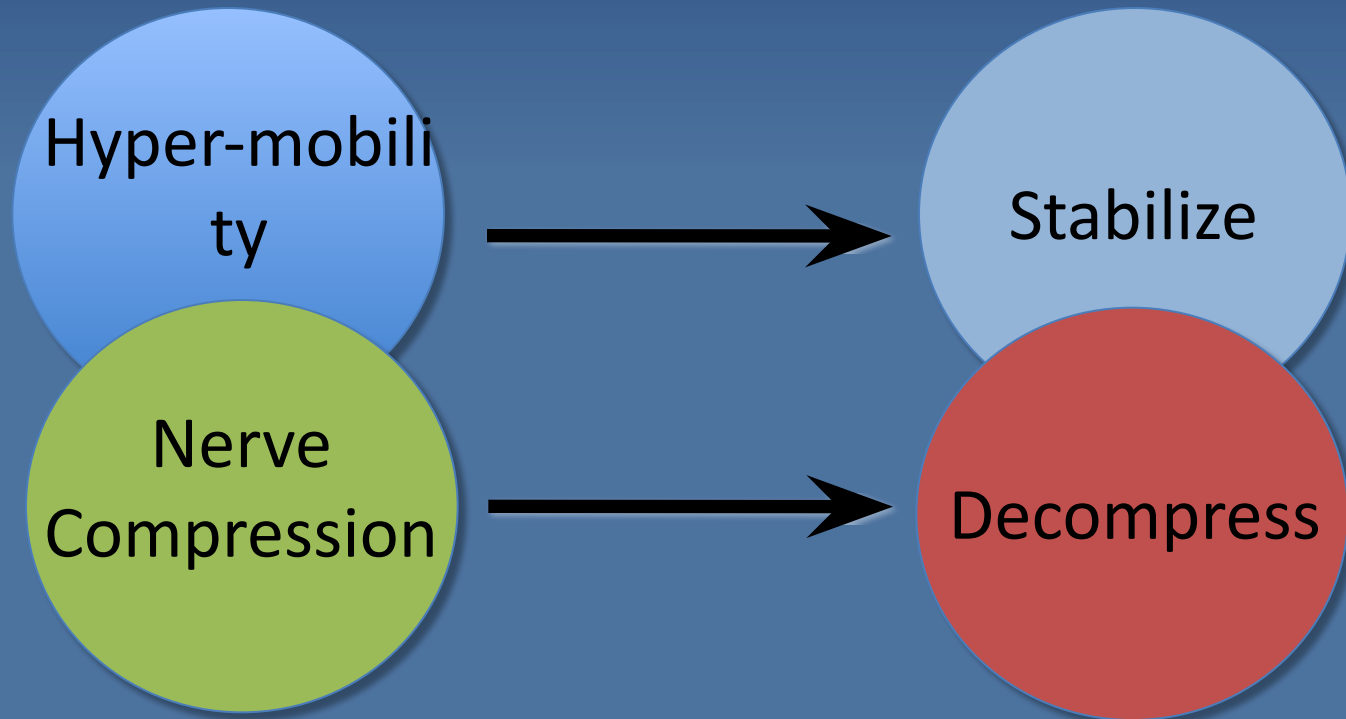
Surgery

- Indications
 - Major or progressive muscle weakness
 - Radiculopathy for 4-6 weeks that has failed conservative treatment
 - Persistent uncontrolled neck/ back pain after 6 months of conservative treatments



Spondylolisthesis

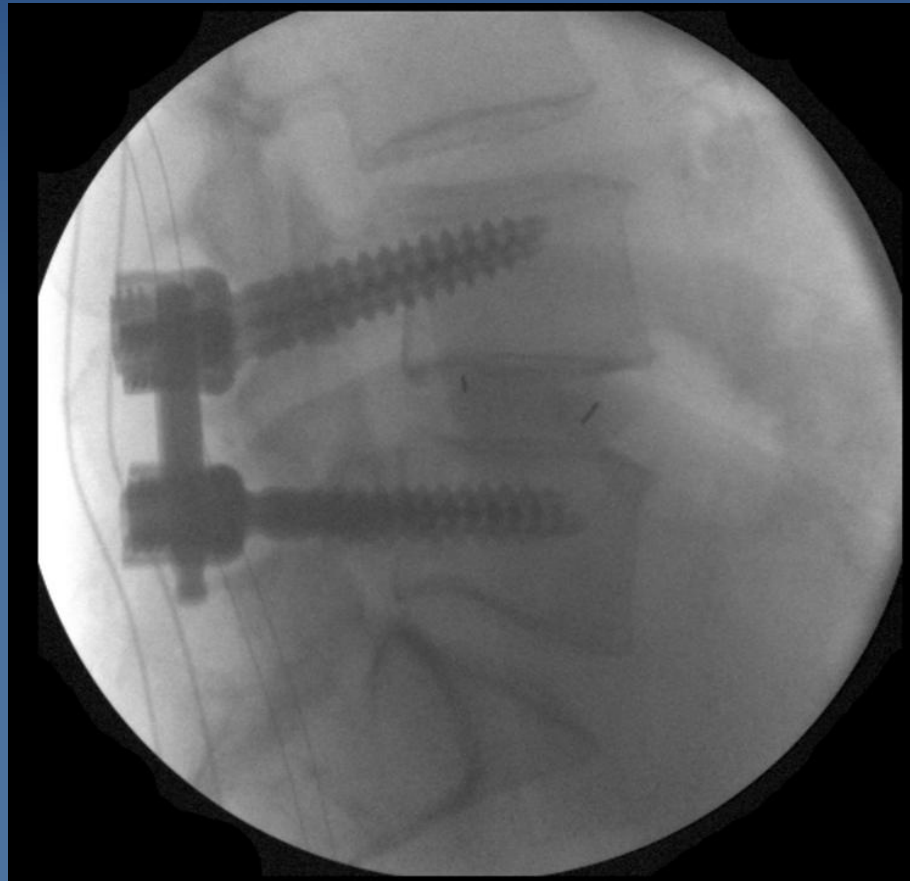
Treatment Goals



Hyper-mobility

Operative Treatment

Minimally Invasive Stabilization



Key Points

1. One MUST have a correct diagnosis: Correlate imaging studies with patient symptoms
2. A pinched spinal nerve causes radicular symptoms, NOT neck or back pain!!
3. Good indications for surgery- nerve compression, hyper-mobility, and unbalanced curves
4. Exhaust all non-operative treatments before considering surgery
5. Minimally invasive surgery offers many advantages

Thank You!



 **ProOrtho**
a division of
PROLIANCE SURGEONS INC., P.S.

 **SMISC**
Seattle Minimally Invasive Spine Center

Mount Rainier- 14,411 feet
July 4, 2014